

The injured eye – practical management guidelines and referral criteria for the rural doctor

Naidu K, MBChB, FCOphth(SA)
Dept of Ophthalmology
Nelson R Mandela School of Medicine
University of KwaZulu-Natal

Correspondence to: Kavitha Naidu, e-mail: kavi1910@yahoo.com

Abstract

Ocular trauma encompasses a wide spectrum of mechanisms and presentations, affecting the orbit, globe of the eye, optic nerve and adnexae. The causative injuries range from the relatively superficial to those that threaten sight. The rural doctor plays a vital role in the initial management of patients with ocular trauma and his/her decisions and treatment can influence the patient's final visual outcome. This article serves to classify ocular trauma and to provide management guidelines for treating minor trauma and initiating proper care for injuries that require referral to specialist ophthalmologists.

SA Fam Pract 2006;48(7): 39-45

Box 1: Ten common terms associated with eye injuries:

1. Afferent pupillary defect
2. Chemosis
3. Hyphaema
4. Uveal prolapse
5. Traumatic cataract
6. Vitreous haemorrhage
7. Endophthalmitis
8. Proptosis
9. Blowout fracture
10. Diplopia

INTRODUCTION

Ocular trauma is an extensive topic. The rural doctor requires a basic classification for correct management and to ensure the collection of accurate clinical data for cases requiring referral. Of importance are the mechanisms of the ocular injury, which are illustrated in Table I.

Socio-economic factors play a major role in the spectrum of injuries sustained by a specific population. In rural areas, the injuries tend to be related to agricultural labour, alcohol abuse and concomitant assault, and

occur predominantly in males and illiterates.¹

Traditional healers may form part of the referral process. They should be educated to promote simple preventative measures, such as the use of protective eyewear. The rural doctor should establish an amicable relationship with the traditional healer and advise him or her on those emergencies requiring referral.

GENERAL GUIDELINES

When confronted with ocular trauma, the practitioner should firstly take a

Table I. Mechanisms of eye injuries

1. Mechanical:	a. Foreign bodies on the superficial eye and adnexae b. Contusion injuries, i.e. injuries with a blunt object c. Penetrating injuries, i.e. injuries with a sharp object
2. Chemical	
3. Thermal	
4. Combination injuries, e.g. firework injuries, which may include thermal, chemical and contusive or penetrating injuries	

Table II. Important features in the history

1. Mode of injury, i.e.
- Exact causative mechanism
- Object inflicting the injury
- Accidental or assault
2. Time to presentation
- Delayed presentation of penetrating eye injuries increases the risk of endophthalmitis.
3. Concurrent injuries elsewhere on the body.
4. Medical, past ocular and family history

It's the shell that makes Ecotrin safer.

Safety-Coated Ecotrin[®] 81mg

The miracle of Aspirin made safer.

Each tablet contains Aspirin 81mg. Reg No: 29/2.7/0787
Pharmatrica (Pty) Ltd, 33 Hubert Road, New Centre, Johannesburg 2001
Under licence from Goldshield Pharmaceuticals Ltd. U.K.

Table III. Specific ocular examination

<p>a. Visual acuity with a Snellen chart</p> <p>b. Assessment and documentation of the injury with proper reference to the anatomical structures. Note - appearance of the orbital rims, eyes and adnexae, i.e. presence of proptosis, enophthalmos or displacement of the globes.</p> <p>c. Examination of the upper and lower lids and lid margins for lacerations.</p> <p>d. Examination of the globes by gently opening the eye- Note the - conjunctiva - sclera - cornea - anterior chamber - iris - pupil Look for abrasions, lacerations, foreign bodies or debris, iris tears, pupil irregularity.</p> <p>e. Pupillary responses – exclude an afferent pathway defect, which indicates severe injury.</p> <p>f. Direct ophthalmoscopy - to assess the red reflex firstly, - then, on closer examination, to assess the optic nerve and macula and to exclude a vitreous haemorrhage or retinal detachment.</p> <p>g. Confrontational visual fields.</p> <p>h. Assessment of ocular motility in all directions.</p>
--

comprehensive history of the events leading to, and timeline surrounding, the injury (see Table II). Secondly, on examination of the patient, an ocular assessment as outlined in Table III should be performed after the general examination.

MECHANICAL INJURIES

a. Foreign bodies on the eye

Protective eyewear is essential when working with any heavy machinery or power tools, and when hammering, chiselling or knocking, especially metal on metal.

Most small superficial foreign bodies can be removed with a cotton-tipped applicator after instillation of topical anaesthetic drops, which are available in a single usage preparation. These drops assist in examining a patient with a painful, tearing eye. They should never be

dispensed to the patient, however, as they can lead to over-usage and result in corneal epithelial loss and significantly interfere with corneal immunity.²

Deeply embedded foreign bodies require removal under the illumination of a slit lamp. If there is a suspicion that the foreign body penetrated the eye, the patient will require an X-ray of the orbit and referral to an ophthalmologist.

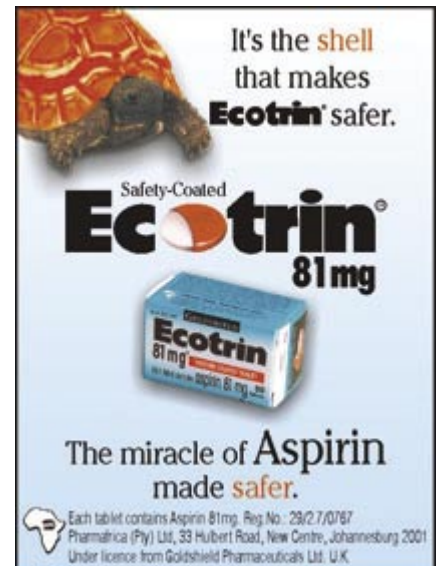Grinding or welding injuries that result in a small piece of metal on the eye often have a rust ring, which is difficult to remove without magnification. These patients sometimes complain of 'arc eye', which presents as painful, injected eyes as a result of welding for long periods without protective eyewear. The treatment of arc eye is given in Table IV.

Table IV. Treatment of arc eye

<ol style="list-style-type: none"> 1. Topical anaesthetic drops 2. Double eye padding 3. Analgesia orally 4. Weak topical steroid drop if marked inflammatory reaction
--

Table V: Signs of a blowout fracture

<ol style="list-style-type: none"> 1. Periocular ecchymosis and oedema 2. Subcutaneous emphysema 3. Enophthalmos (eye appears smaller) 4. Infraorbital numbness 5. Limitation of eye movement especially in upward or lateral gaze 6. Eye deviated – appears squint



Subtarsal foreign bodies can also be removed under topical anaesthetic drops. The upper lid must be everted gently with a cotton-tipped applicator by placing pressure on the tarsal plate while the patient looks down. The foreign body can then be seen and removed with the applicator.

Insects on the eye may require surgical removal under general anaesthetic with the use of a microscope. Bee and wasp stings to the cornea cause a toxic inflammatory reaction in the eye and require analgesia, specialist assessment and surgical treatment, depending on the severity of the reaction and whether the stinger is amenable to removal.³

b. Non-penetrating/contusion injuries

Lid abrasions and minor haematomas without any concurrent globe injury or drop in vision may be managed conservatively with analgesia and cold compresses. Any direct impact to the globe or the orbit requires referral to a specialist.

An orbital blow-out fracture is caused by a sudden increase in the orbital pressure as a result of a striking object that is greater than 5 cm in diameter, such as a fist or tennis ball.⁴ This results in fractures

Figure 1: A patient with a blowout fracture of the left orbit, showing enophthalmos and restrictive strabismus of the left eye.

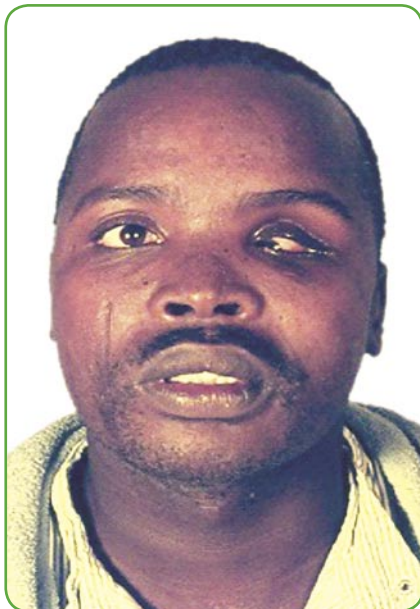
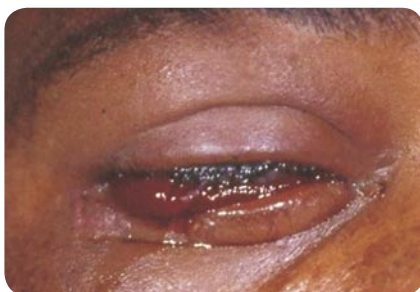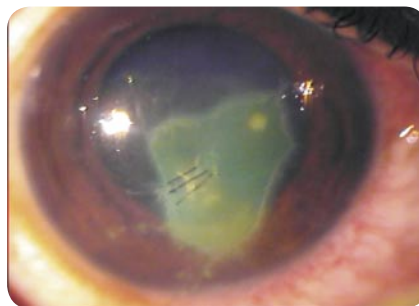


Figure 2: Lid swelling and chemosis after a contusive eye injury



of the bones forming the orbit. The floor of the orbit and the medial wall are involved most commonly and, being extremely thin, they fracture as a pressure wave extends across the orbit. This potentially spares the eyeball from rupturing.² The patient will complain of deterioration in vision, numbness of the cheek, side of the nose and upper lip, and diplopia (double vision). The signs of a blowout fracture are listed in Table V, and the injury is illustrated in Figure 1. Affected patients should be referred for a CT scan of the orbits to decide whether surgical orbital repair is required.

Figure 3: Corneal abrasion with underlying sutured corneal laceration – fluorescein dye staining over abrasion.

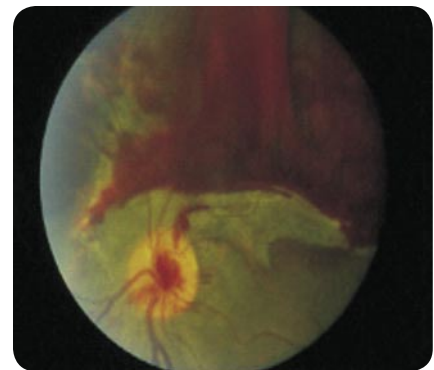


Proptosis of the eye after a contusive injury (see illustration in Figure 2) implies a subperiosteal or retrobulbar haematoma, especially if there is subconjunctival haemorrhage and chemosis with taughness of the eyelids. The pupillary reactions must be documented, and the patient should be referred for an orbital CT scan and drainage of the haematoma.

Lid swelling and extensive subconjunctival haemorrhage with swelling, giving the appearance of a 'jelly roll' of conjunctiva, should alert the practitioner to a severe ocular injury with probable posterior globe rupture. An additional clue is a deepened anterior chamber of the eye and poor visual acuity, with an afferent pupillary defect.⁴

A corneal abrasion can be recognised by instilling fluorescein drops onto the eye. This dye stains the damaged epithelial cells and thus outlines the abraded area (see Figure 3). The treatment of corneal abrasions is set out in Table VI. Patching of the abraded eye is felt to be counterproductive to healing, as it reduces the oxygen supply to the cornea. It also increases the corneal temperature and the micro-organism replication rate, leading to infection.²

Figure 4. Vitreous haemorrhage



Hyphaema, blood in the anterior chamber of the eye, is a common presentation of contusive eye injuries (35% of closed globe trauma).² Most patients are younger than 20 years old and the male to female ratio is 3:1.² Hyphaema is easily recognised as a level of blood in the anterior chamber, obscuring the iris and sometimes the pupil.

Figure 5. Retinal detachment

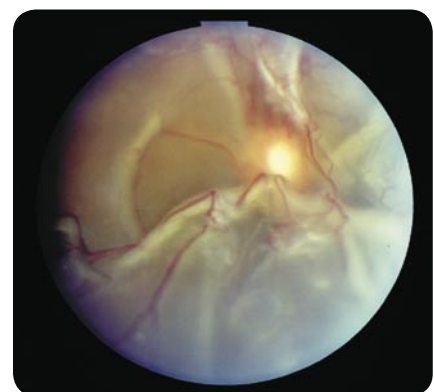

Table VI. Treatment of corneal abrasions

1. Chloramphenicol ointment
2. Analgesia
3. Eye pad
4. Referral to rule out intraocular damage

The blood may organise into a clot in the anterior chamber or be comprised of dispersed circulating red blood cells, making the details of the iris and pupil appear unclear.

A full hyphaema, often called an 'eight-ball' hyphaema, sometimes occurs, giving the appearance of a dark red to brown-black cornea, with no view of the anterior chamber. This is associated with an elevated intraocular pressure and severe eye pain. All patients with a hyphaema need referral for bed rest, topical steroid therapy, control of intraocular pressure and surgical anterior chamber washout if necessary.

Other injuries that require referral are:

- A mid-dilated pupil, indicating a traumatic mydriasis
- Irregularities in the iris appearance, indicating iris sphincter or root tears
- Opacification of the lens – a cataract forms
- Rupture or dislocation of the lens

In patients with clear media, examination with the direct ophthalmoscope may exclude posterior segment haemorrhage or injury (see Table VII). However, any non-penetrating eye injury associated with deterioration in visual acuity, or where the impact on the eye was significant, should be referred.

**c. Penetrating/perforating injuries
Lacerations**

Lid lacerations not involving the lid margin should be sutured. However, those with tarsal plate, levator or lacrimal puncta and canalicular damage need specialist repair. Associated haematomas of the lids may be treated with

Table VII. Sequelae of contusive eye injuries

ANTERIOR SEGMENT	
Orbits	Orbital rim/blowout fracture Retrobulbar haemorrhage
Lids	Periorbital haematoma Traumatic ptosis Lid abrasion Lid rupture
Conjunctiva	Haemorrhage Chemosis
Sclera	Anterior or posterior rupture
Cornea	Abrasion Rupture
Anterior chamber	Hyphaema Uveitis
Iris	Sphincter rupture
Angle	Angle recession
Ciliary body	Ciliary body shutdown
Pupil	Traumatic mydriasis
Lens	Cataract Subluxation/dislocation Rupture
POSTERIOR SEGMENT	
Vitreous	Haemorrhage
Retina	Retinal swelling/oedema/ haemorrhages Retinal tears Macular hole Retinal detachment
Choroid	Haemorrhage Choroidal rupture
Optic nerve	Optic neuropathy Optic nerve avulsion
Globe	Total rupture

cold compresses, antibiotics and analgesia.

Subconjunctival haemorrhages are self-limiting and only require the patient to be reassured.

Ocular lacerations with uveal prolapse present as a brown knuckle of protruding tissue. (See figures 6 and 7).

Figure 6. Large corneal laceration.

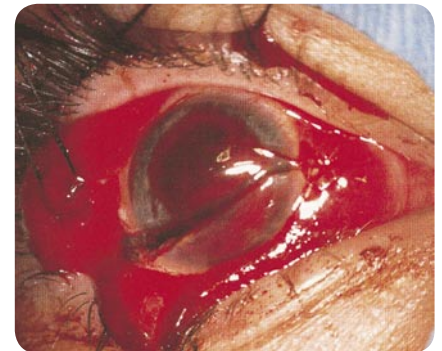
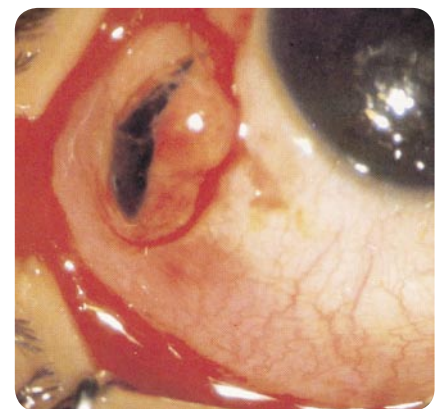


Figure 7. Scleral laceration with uveal and vitreous prolapse.



Other features of a corneal, scleral or corneoscleral laceration include:

- Hyphaema,
- A shallow or flat anterior chamber of the eye
- Iris and lens damage, with a distorted pupil
- A ruptured cataract

Ocular lacerations are managed by covering the eye with an eye pad, administering a topical antibiotic and controlling the patient's pain with oral analgesics. The patient needs to be referred to the nearest ophthalmologist for surgical repair as soon as possible. If a delay in specialist care is anticipated, a

Table VIII. Epidemiology of intraocular foreign bodies^{2,5}

Incidence:	18-41%
Age:	Range 3-79 years Average 29-38 years
Sex:	Males 92-100%
Cause:	Hammering steel or brick: 60-80% Power or machine tool accident: 18-25% Weapon related: 19%

systemic oral antibiotic and tetanus prophylaxis should be administered.²

A disorganised eye occurs in severe injuries and is described when the ocular anatomy is totally distorted and there is a complete loss of vision.

Gunshot injuries

Gunshot injuries are regarded as perforating eye injuries, as they are caused by high-speed projectiles that pass through the eye. Bullets are blunt missiles travelling at a high velocity with large amounts of kinetic energy. They cause significant damage to the eyeball and socket, as opposed to a sharp piece of shrapnel, which may cause a more well-defined laceration with less intraocular damage. The bullet sometimes grazes past the globe without penetration. In comparison to an open globe injury, these injuries carry a low risk of orbital infection due to the speed and heat at which the impact occurs.

All these patients need a CT scan to exclude brain and sinus injury, assess the degree of orbital damage and exclude the presence of a retained bullet or pellet fragments. Patients may develop a slow extra or subdural haemorrhage with raised intracranial pressure and deterioration in their Glasgow coma scale. These patients obviously need neurosurgical intervention first before their eye problems are addressed.

Foreign bodies

Intraocular foreign bodies are usually found in patients who give a history of sudden projectile, penetrating ocular injuries, where the patient was not wearing any ocular

protection. The epidemiology of intraocular foreign bodies is given in Table VIII (also see illustrations in Figures 8 to 11).

Figure 8. Intraocular foreign body embedded in the retina of a patient.

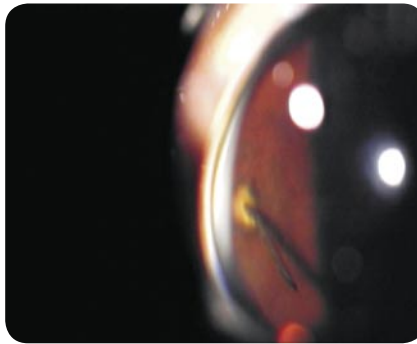


Figure 9. Foreign body from Figure 8 removed from the eye.

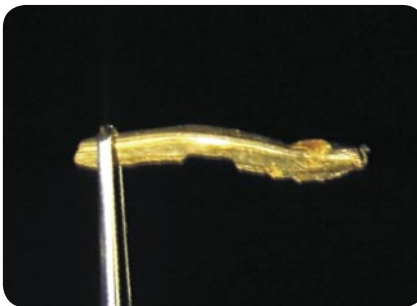



Figure 10. Metallic foreign body measuring 6 mm.

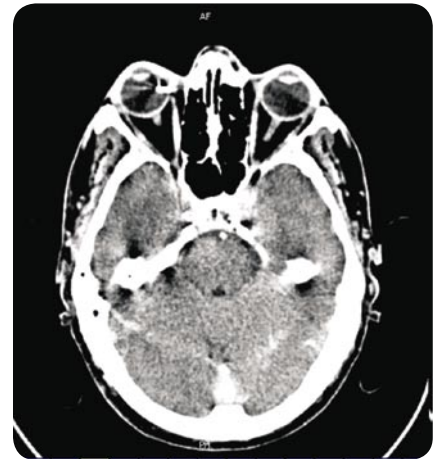

Due to the often small size of the foreign body and the speed at which it enters the globe, the entry wound on the eye may be small and may

seal spontaneously. Patients may not be aware that there is a foreign body in their eye, particularly if it is small and composed of an inert substance. Their symptoms may be minimal, aside from mild discomfort, and they commonly complain of 'floaters' in the eye.⁶

All patients with suspected intraocular foreign bodies need an X-ray or CT scan of the orbits and then referral. Once the position and size of the foreign body have been confirmed, the patient will probably undergo a pars plana vitrectomy to remove the foreign body surgically.

Figure 11. CT scan of the patient in Figure 8 showing a large metallic foreign body in the right eye.



Stab injuries to the orbit

Stab injuries to the orbit require urgent referral, as they result in severe orbital sepsis and endophthalmitis in two to seven per cent of cases if the globe is penetrated or perforated. These patients require prophylactic antibiotics and an orbital and brain CT scan to exclude an intracranial tract, orbital wall breach or sinus damage. Penetrating injuries to the globe as a result of wood or

Table IX. Stepwise approach to open globe injuries for the non-ophthalmologist:⁷

1. Assume that all open globe injuries involve an intraocular foreign body.
2. Shield the eye with a light dressing.
3. Prescribe systemic medication for pain/anxiety/nausea as needed.
4. Refer the patient to the nearest ophthalmological institution. A personal discussion with the ophthalmologist is highly advised.
5. Unless it is an injury with a high infective risk and/or a long delay in transportation is expected, there is no need to start antibiotic therapy, although tetanus prophylaxis may be given.

wire, especially copper, are also high-risk injuries for intraocular and orbital sepsis and require immediate referral.

Sympathetic ophthalmitis

Sympathetic ophthalmitis is a rare, bilateral, sight-threatening, autoimmune panuveitis that occurs after injury to one eye (the exciting eye), followed by a latent period and then involvement of the uninjured globe (the sympathising eye). This condition can occur as early as 10 days or as late as 50 years following the injury.

In injured eyes where there is no potential for vision, it is advisable to remove the eye within 10 to 14 days of the injury. This requires prompt referral of all patients in this risk category. Improved and timeous wound closure and early removal of severely damaged eyes have significantly reduced the incidence of sympathetic ophthalmitis ($\pm 0,4\%$).²

Table IX provides an approach to open globe injuries for the non-ophthalmologist.

2. CHEMICAL EYE INJURIES

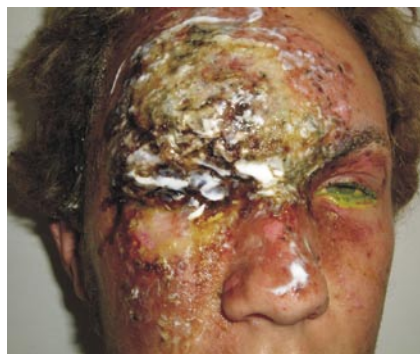Chemical injuries are commonly caused by household detergents, disinfectants, solvents, cosmetics, drain cleaners, ammonia and bleach. Agriculturally related chemicals, such as fertilisers and pesticides, and industrial chemicals, such as caustic solutions and solvents, can cause complete ocular destruction.⁸

Early treatment is crucial and referral is urgent. The immediate management, after establishing the causative chemical or irritant, is to irrigate the eye with copious amounts of normal saline or sterile water. Topical anaesthetic drops should be used to diminish eye pain and an eye pad should be applied before referral. Concentrated acid or alkaline burns must be referred as a matter of urgency. Alkalis in particular tend to penetrate the eye and continue causing further damage.

3. THERMAL EYE INJURIES

Eye injuries caused by a spark from a match or fire or by boiling water can vary in severity. The former usually will result in a corneal abrasion and some debris in the fornices of the eye. The latter may be mild or very severe, depending on the circumstances surrounding the injury. Concurrent skin and scalp burns are common and require immediate attention. The thermal burn to the eye is often a corneal abrasion and sometimes is associated with a conjunctival abrasion. The degree of lid involvement varies. All such injuries require specialist referral.

Figure 13. Patient with a severe firework injury to the face and eyes.



4. COMBINATION EYE INJURIES

These injuries vary depending on the cause. They usually occur as a result of a firework injury, a motor vehicle accident or an explosive or blast injury. The patient requires a thorough examination at a slit lamp and sometimes under anaesthesia, and therefore will need immediate specialist referral. The eye should be kept covered with a light dressing and analgesia must be administered orally. It is very important for the referring doctor to exclude injuries elsewhere on the body before consulting the ophthalmologist.

SUMMARY

Ocular trauma requires a fully functional referral pattern for the rural doctor. One should establish open communication lines with the nearest

referral centre ophthalmologist to ensure uncompromising, quality patient care at all times. Education on simple measures such as the use of protective eyewear should not be underestimated and requires communication with employers. The role of the traditional healer in education and referral of patients should be considered. This article provides rural doctors with basic guidelines in treating patients and will hopefully improve primary healthcare and earlier referral.

ACKNOWLEDGEMENTS

All photographs courtesy and copyright of the Department of Ophthalmology, Nelson Mandela School of Medicine, University of KwaZulu-Natal. 🙏

See CPD Questionnaire, page 50

P This article has been peer reviewed

REFERENCES

1. Nirmalan PK, Katz J, et al. Ocular trauma in a rural south Indian population: the Aravind Comprehensive Eye Survey. *Ophthalmology* 2004;111(9):1778-81.
2. Kuhn F, Pieramici DJ. Ocular trauma - principles and practice. Thieme Medical Publishers; 2002.
3. Kirk RW, Andrew JW, et al. External disease and cornea. Basic and Clinical Science Course. American Academy of Ophthalmology; 1998. p. 361-2.
4. Kanski JJ. Clinical ophthalmology – a systematic approach. Butterworth-Heinemann. 2003.
5. Visser L. Common eye emergencies and procedures – lecture notes for general practitioners; 2005.
6. Narsing AR, Blackman HJ, et al. Intraocular inflammation and uveitis. Basic and Clinical Science Course. American Academy of Ophthalmology; 1998. p. 128-9.
7. Kirk RW, Andrew JW, et al. External disease and cornea. Basic and Clinical Science Course. American Academy of Ophthalmology; 1998. p. 357-9.
8. Sceufele TA, Blomquist PH. Spectrum of ocular trauma at an urban county Hospital. *Tex Med* 2004;100(12):60-3.
9. Viestenz A, Kuchle M. Blunt ocular trauma. Part I: blunt anterior segment trauma. *Ophthalmologie* 2004;101(12):1239-57.
10. Viestenz A, Kuchle M. Blunt ocular trauma. Part II: Blunt posterior segment trauma. *Ophthalmologie* 2005;102(1):89-99.