

Glaucoma in general practice

Gundry BN, MBChB, FCOphth(SA)

Department of Ophthalmology, Nelson R Mandela School of Medicine,
University of KwaZulu-Natal

Correspondence to: Dr BN Gundry, e-mail: be@tiscali.co.za

Abstract

Glaucoma is a silent condition very rarely presenting with headaches and only leading to decreased vision in the very advanced stages. Disc cupping and intraocular pressure measurement are important features in making the diagnosis. Acute angle closure is very rare and needs urgent referral. Most patients will be well controlled with medical therapy alone

SA Fam Pract 2006;48(7): 46-49

Introduction

Glaucoma is the second leading cause of blindness in the world, only being surpassed by cataract blindness, which, unlike glaucoma, is surgically curable.¹ It is an optic neuropathy that is characterised by structural optic disc changes and visual field loss and is usually associated with an increased intraocular pressure, although not always (a common misconception). Other common misconceptions about glaucoma are summarised in Box 1. The most common form of glaucoma is primary open angle glaucoma, which is associated with a raised intraocular pressure. Patients with normal intraocular pressure but with field loss or glaucomatous disc changes are referred to as having normal tension glaucoma. Primary angle-closure glaucoma is much rarer and is found in patients who are predisposed due to specific anatomical features of the anterior part of the eye. It is generally more common in Asia and is found in South Africa in persons of mixed ancestry and in the Cape Malay population. There are other types of obstruction to aqueous outflow commonly caused by trauma or inflammation. We are beginning to understand the multifactorial causes of glaucoma (other than purely raised intraocular pressure) and the complex neuronal messaging responsible for premature

ganglion cell death. At present, the only treatment available is lowering of the intraocular pressure, although the body of evidence for "neuroprotection" as an intervention is growing.

Box 1: Common misconceptions about glaucoma

1. Glaucoma is *always* caused by high intraocular pressure
2. Headache is a frequent presentation of glaucoma
3. Poor vision is a common presentation of glaucoma
4. Visual fields detect early glaucomatous damage
5. Untreated high intraocular pressure leads to blindness from glaucoma

Prevalence

The prevalence of glaucoma in the American population is 1.5% to 2%, with 10% to 15% of first-degree relatives of patients diagnosed with primary open angle glaucoma likely to go on to develop the disease.² Two population-based surveys undertaken in Elim, Limpopo (1985) and in the Ingwavuma district in KwaZulu-Natal (1991) to determine the prevalence and causes of blindness saw glaucoma as the cause in 6% and 23% of

cases respectively.³ In the planning of blindness prevention programmes in South Africa, a figure of 10% is used for blindness due to glaucoma. Glaucoma is the only common cause in the top three causes of blindness in both the first world (Europe and North America) and in the developing world (Latin America, Asia and Africa). Data from the United States estimates that 2.25 million Americans aged 40 years and older have glaucoma, half of which are unaware that they have this disease.² Elevated intraocular pressure affects an estimated 5 to 10 million Americans, putting them at greater risk of developing glaucoma.² In the USA, more than 3 million visits to ophthalmologists are made to monitor glaucoma/intraocular pressure, and more than 1 million patients are on treatment.²

Screening and diagnosis

There is no easy screening tool with high specificity and sensitivity available for glaucoma as yet, although there are numerous trials underway evaluating new visual field testing technology, usually combined with optic disc appearance and/or intraocular pressure measurement. Visual field testing with the current standard technology can only detect glaucomatous damage after a significant amount of retinal ganglion cells (>50%) has already been lost. The appearance of the optic nerve

will usually alert the physician to the suspicion of glaucoma, as this structural loss will be seen before there is any functional loss. Disc appearance is the most accurate method of assessing whether or not a patient has glaucoma. The vision as measured by conventional acuity testing is usually unaffected until late in the disease process, unless the visual field loss encroaches onto the fixation point early on.

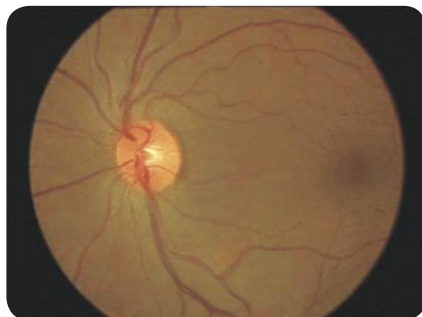
Patients should be referred to an ophthalmologist if any of the following features are found on examination:

1. Increased cup-disc ratio (see Figure 1)
2. Haemorrhages at disc (see Figure 2)
3. Raised intraocular pressure
4. Visual field deficits

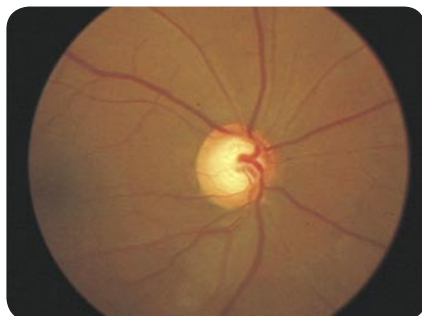
The glaucomatous optic disc is diagnosed when there is:

1. Increased cup to disc ratio
2. Optic disc haemorrhages
3. Peripapillary atrophy

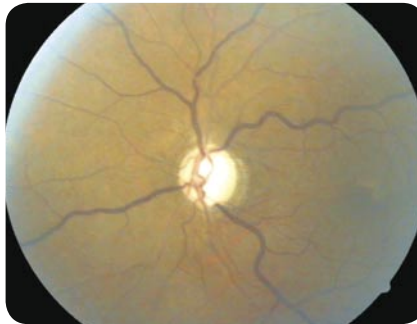Figure 1: Progressive optic disc cupping



Normal disc with healthy rim.
Cup : disc ratio of approximately 0.2



Early cupping-note thinner rim and increased cup : disc ratio of approximately 0.7



Advanced cupping (0.9)-note pallor of disc and barely discernible rim shown by veins dipping backwards over rim.

Most glaucoma is detected by optometrists, who usually screen intraocular pressure with an air-puff tonometer as a routine part of their examination, or it is detected in individuals who have been identified as at risk due to a family history and are being monitored. These patients would usually then be referred to an ophthalmologist, who would follow them up and initiate treatment if and when required. The air-puff tonometer tends to overestimate the intraocular pressure, particularly in patients with a strong blink reflex. It is important to remember that the majority of patients with a raised intraocular pressure (above 20 but less than 30) will not go on to develop glaucoma and are referred to as ocular hypertensives. They are at increased risk of glaucoma, however, and usually require lifelong follow up. Contrary to popular belief, most forms of glaucoma are not associated with headache and the vast majority of patients are totally free of any symptoms of a higher than normal intraocular pressure, except in the case of a sudden rise in pressure as occurs in an attack of angle-closure glaucoma (see box 2).

Box 2: Diagnosis and treatment of acute angle-closure glaucoma

1. Presents with sudden onset of severe pain in affected eye, with headache, nausea and vomiting.
2. Affected eye red with mid-size pupil unresponsive to light and hazy cornea.
3. Patient may describe halos

around lights due to corneal oedema.

4. Anterior chamber may appear shallow.
5. Urgent decrease in intraocular pressure – administer Acetazolamide 500 mg IVI stat (if available) or alternatively Acetazolamide 500 mg po-stat.
6. Patients usually require anti-emetics.
7. Urgent referral to ophthalmologist required.
8. Unless there is a delay in transfer, there is usually no need to administer Pilocarpine drops, as they usually are not effective when the intraocular pressure is above 50 mm Hg due to iris ischaemia. Should there be a delay, start Pilocarpine 2% qid in *both* eyes, as the fellow eye is usually also at risk.

Treatment

The aim with glaucoma therapy is to detect the disease early on and thus prevent irreversible optic nerve damage with resultant visual field defects. The only modifiable risk factor (in terms of evidence-based medicine at present) that can be treated is intraocular pressure. This is achieved in the majority of cases through medical therapy, with surgery usually being reserved for when medical treatment fails or for intolerance to medical therapy. The only form of glaucoma that necessitates emergency treatment is that in which there is a sudden increase in intraocular pressure, in which case the patient will present with severe pain, usually accompanied by headache, nausea and vomiting. The eye will be red, with a mid-dilated pupil not responsive to light.

Medical ion

Prostaglandins/prostamides (latanoprost, bimatoprost, travaprost)
This group of drugs is the treatment of choice in most cases and has the best efficacy in terms of lowering the intraocular pressure by increasing aqueous outflow from the eye and in terms of having the fewest side effects. These drugs also have the easiest dosing, with a once-

a-day application. There are very few contraindications to these medications and the main side effects that have been noticed are an initial conjunctival injection, which usually settles with time, darkening of the iris colour and longer, thicker eyelashes.

Topical beta blockers

Prior to prostaglandins, topical beta blocker therapy was the gold standard. This group of medications works by decreasing aqueous production and is dosed twice daily. The contraindications are as for systemic beta blockers (although betaxolol is marketed as a beta-1 selective agent with less bronchoconstrictive effect).

Carbonic anhydrase inhibitors

This group of drugs may be given topically or systemically to reduce aqueous humour production.

Topical: Dorzolamide and Brinzolamide

Systemic: Acetazolamide. Due to the side-effect profile, this is usually only used temporarily or in an emergency where a large drop in intraocular pressure is required in a short space of time.

Fixed combination drops (Dorzolamide+Timolol and Latanoprost+Timolol)

Both the prostaglandins and carbonic anhydrase inhibitors are available in a fixed combination with beta blockers. These may help with compliance issues, and are also slightly more effective.

Alpha agonists (brimonidine, apraclonidine)

These agents work by decreasing aqueous humour production and increasing aqueous outflow. It is thought that these agents may have neuroprotective properties.

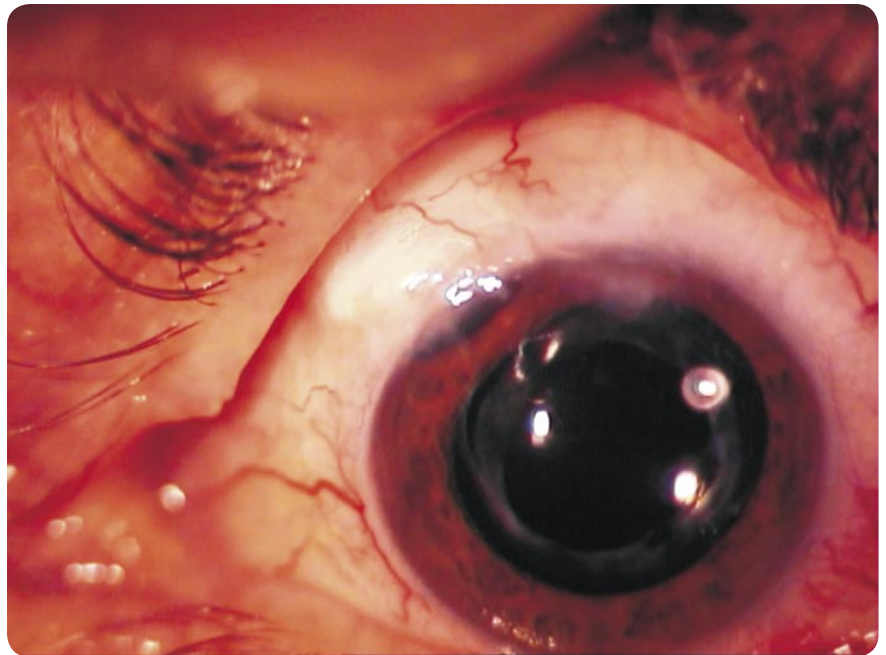
Miotics (pilocarpine)

This drug is seldom used today, although it may still be useful in angle-closure glaucoma patients. It has a poor side-effect profile and a laborious dosing regimen, at three to four times daily.

Hyperosmotic agents (mannitol, isosorbide, glycerol)

These are used systemically in emer-

Figure 3: Trabeculectomy surgery site – note conjunctival ‘bleb’ filtering aqueous under the conjunctiva and the peripheral iridectomy.



gency situations only.

Surgical

Laser

Lasers may be used to create a small hole, called a peripheral iridotomy (PI), in the peripheral iris to allow aqueous trapped behind the iris to circulate into the anterior chamber and drain out via the normal outflow pathway. This is most commonly performed in angle-closure glaucoma patients. Laser may also be applied to the trabecular meshwork in what is called laser trabeculoplasty (Argon laser trabeculoplasty or selective laser trabeculoplasty) to increase outflow.

Filtration surgery

Trabeculectomy is the gold standard for glaucoma filtering surgery (see Figure 3). It entails the creation of a small ostium underneath a flap of sclera that allows aqueous to slowly drain out of the eye and into the subconjunctival space. The problem with this surgery is that most eyes eventually become so scarred that the ostium closes, unless an antimetabolite is used intraoperatively. The latter, however, produces its own complications, such as late wound leaks and the threat of infection.


Seton implants are tubes implanted

into the anterior chamber that communicate with the subconjunctival space via a plate, which creates a reservoir into which the aqueous drains. Some of these implants may have a valve mechanism to prevent over-drainage and the complications of a hypotonic eye. The tubes seem to have a similar “survival” rate to a trabeculectomy, although there is a lot of work being done on these valves at present to produce a more predictable and long-lasting drainage device.

Conclusion

Glaucoma is the second leading cause of blindness and can usually be prevented by simple screening methods of intraocular pressure measurement and visualization of the optic disc at a primary care level effecting appropriate referral to ophthalmology services for further management. 🙋

[See CPD Questionnaire, page 50](#)

 This article has been peer reviewed

References

1. World Health Report web site 18/08/2006 : www.scielosp.org/scielo.php?pid=S0042-96862004001100019&script=sci_arttext
2. American Academy of Ophthalmology Basic and Clinical Science Course. Section 10 of 12 volume series; 1997 edition p 9.
3. Bureau for the Prevention of Blindness. Community Eye Health Workshop Booklet.