

# Do normal C-reactive protein levels exclude the diagnosis of cryptococcal meningitis?

Levay PF, Gryffenberg H

(SA Fam Pract 2006;48(2): 14)

**To the Editor:** South Africa is presently experiencing an epidemic of HIV-associated diseases, including cryptococcal meningitis. *Cryptococcus* is a fungal-type organism, and disseminated or cryptococcal meningitis is an AIDS-defining disease, occurring in up to 10% of patients with AIDS. In Durban, South Africa, cryptococcal meningitis was the initial AIDS-defining illness in 84% of HIV patients,<sup>1</sup> while in Pretoria it was found to be the presenting cause for patients with HIV and meningitis in 50% of patients.<sup>2</sup> Its incidence at Pretoria academic hospitals has more than doubled over the past year (Levay, unpublished findings). The clinical presentation of patients with cryptococcal meningitis varies from headache (>95%) to coma. The diagnosis of cryptococcal meningitis presently rests on lumbar puncture demonstrating cryptococcal organisms by smear, antigen or culture. This is an invasive and costly procedure and is associated with patient discomfort. It would be ideal if a screening test could be used to exclude this diagnosis based on a simple blood examination, such as C-reactive protein (CRP). This test would mean less discomfort for the patient, in addition to decreased laboratory examination costs, especially as the patients may present with a mild symptom such as headache.

To determine the usefulness of serum CRP levels in patients with cryptococcal meningitis on the day of presentation, a retrospective analysis was done on patients with cryptococcal meningitis. Following ethical clearance from the Ethical Committee of the University of Pretoria, patients were identified by searching the database of the Institute of Pathology at the University of Pretoria. Patients with laboratory tests indicative of cryptococcal meningitis (gold standard criterion used for diagnosis is a positive cerebrospinal fluid culture, antigen or cryptococcal smear) and a CRP level on the day of the spinal tap were

**Table I:** The means of cryptococcal meningitis diagnosis in the study population (n = 204).

	Tested positive	Tested negative
CSF cryptococcal smear	121 (96.03%)	5 (3.97%)
CSF cryptococcal antigen	192 (99.48%)	1 (0.52%)
CSF cryptococcal culture	186 (94.90%)	10 (5.10%)

[CSF – cerebrospinal fluid]

included (see Table I). A normal serum CRP value was defined as  $\leq 10$  mg/l. The data were computerised and statistically analysed using Statistica 6.0.

Of the 308 patients with cryptococcal meningitis that were found in the database, 204 had CRP values for the day on which the lumbar puncture and diagnosis were done. Of these, 72 (35.29%) had CRP levels that were within normal levels (Figure 1). This indicates a sensitivity of 64.71% for elevated CRP for the diagnosis of cryptococcal meningitis diagnosis. Specificity was not calculated.

In the case of certain infections, such as *Pneumocystis jirovecii* pneumonia, CRP levels have been reported to be significantly lower in HIV-positive patients in comparison to HIV-negative patients.<sup>3</sup> There is some evidence that HIV-infected patients may have a suboptimal immune response to infections with lower CRP levels.<sup>4,5</sup> CRP values in HIV-positive patients with

cryptococcal meningitis may therefore have been decreased falsely. Our findings indicate that CRP is a poor screening test for cryptococcal meningitis, missing more than a third of episodes.

In conclusion, our findings do not substantiate CRP as a good screening tool for patients who may present with cryptococcal meningitis. Lumbar punctures should be considered in all patients with a high risk (e.g. HIV) and with symptoms, however mild (e.g. headache), and remain the gold standard for the diagnosis of cryptococcal meningitis.

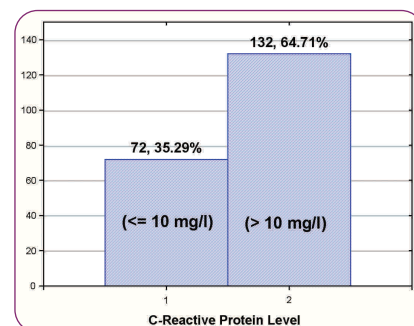
**Levay PF**, MSc, MBChB, MMed (Int) Department of Internal Medicine, Kalafong Hospital, University of Pretoria  
**Correspondence:**  
 peter.levay@up.ac.za

**Gryffenberg H**, Med TechDip Institute of Pathology, University of Pretoria

**References:**

1. Moosa MY, Coovadia YM. Cryptococcal meningitis in Durban, South Africa: a comparison of clinical features, laboratory findings, and outcome for human immunodeficiency virus (HIV)-positive and HIV-negative patients. *Clin Infect Dis* 1997;24:131-4.
2. Schutte CM, Van der Meyden CH, Magazi DS. The impact of HIV on meningitis as seen at a South African Academic Hospital (1994 to 1998). *Infection* 2000;28:3-7.
3. Nuesch R, Bellini C, Zimmerli W. *Pneumocystis carinii* pneumonia in human immunodeficiency virus (HIV)-positive and HIV-negative immunocompromised patients. *Clin Infect Dis* 1999;6:1519-23.
4. Diculencu D, Apetrei C, Iancu LS, Bosnea D. The role of C-reactive protein (CRP) determination in the early diagnosis of infections with opportunistic micro organisms in HIV-infected children. *Rev Med Chir Doc Med Nat lasi* 1995;99:139-43.
5. Storgaard M, Laursen AL, Andersen PL. The C-reactive protein responses in HIV-infected patients with pneumonia. *Scand J Infect Dis* 1993;25:305-9.

**Figure 1:** Number and percentage of 204 patients with proven cryptococcal meningitis with normal or elevated serum C-reactive protein levels on the day of diagnosis.



[1 – normal C-reactive protein level; 2 – elevated C-reactive protein level]