

# A challenging red eye clinical quiz

Dr Derrick Smit, MBChB, Dip Ophth(SA), FC Ophth(SA), MMed(Ophth)(Stell)  
Senior Specialist  
Department of Ophthalmology  
Faculty of Health Sciences  
Stellenbosch University, Tygerberg Hospital  
Correspondence to: Dr Derrick Smit, e-mail: dpsmit@sun.ac.za

## Abstract

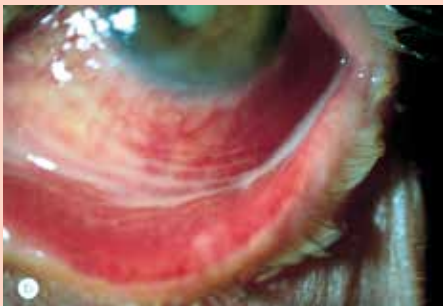The following red eye cases and this clinical quiz is not only aimed at over the counter (OTC) medication, but also illustrates the importance of referring patients who do not respond to OTC medicines or primary medical attention. The case studies are discussed in more detail after the initial case presentations. Read the case studies and decide whether the causes are bacterial, viral, or allergic and decide what treatment you would have prescribed for the patient, or if you would refer the patient.

© Medpharm

S Afr Fam Pract 2014;56(2):110-115

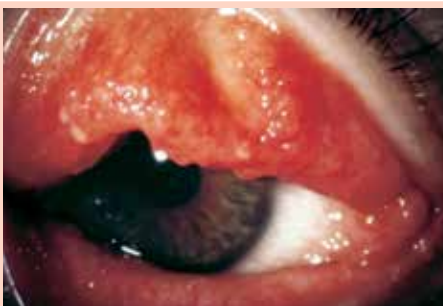## What is the diagnosis and treatment?

### Case 1



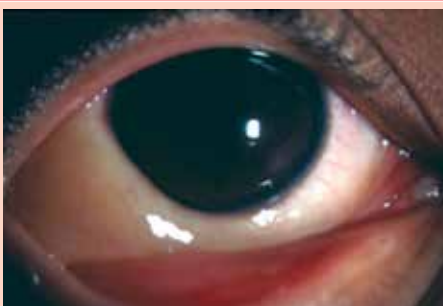A 30 year old male presents with a 3 day history of an uncomfortable red left eye. His visual acuity is unchanged but a mucopurulent discharge is present that causes his eyelids to be stuck together upon waking.

### Case 2



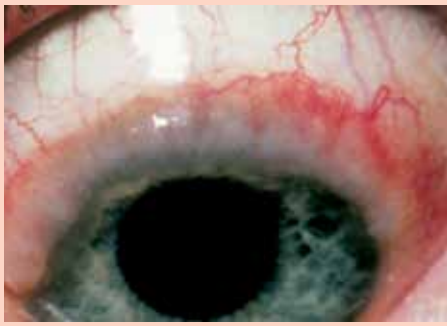
A 20 year old lady complains of redness and discomfort which started in her left eye and spread to her right eye two days later. Her visual acuity is unaffected, she has a watery discharge from both eyes and she is aware of a tender swelling in front of both ears.

### Case 3



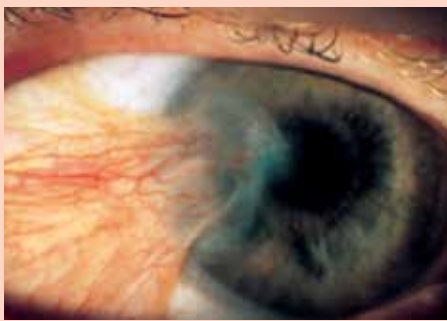
A 14 year old girl complains of recurrent attacks of redness and severe itching of both eyes associated with sneezing and a mucoid discharge from her eyes and nose.

Case 4:



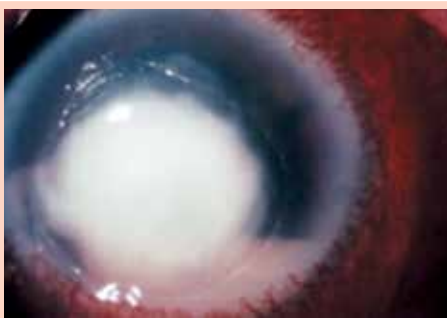An 8 year old boy presents with a 2 year history of intense itching and discomfort in both eyes as well as a thick mucoid discharge. He also mentions that he suffers from asthma.

Case 5



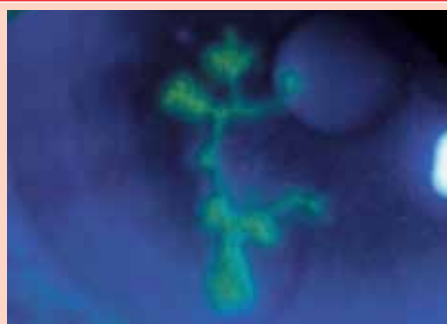
A 40 year old patient present with a 10 year history of discomfort and "something growing" over the left eye.

Case 6



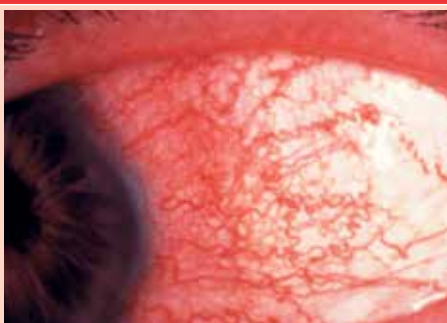A 35 year old patient presents with a 4 day history of a very painful, red right eye with severely decreased visual acuity. He has noticed a sticky discharge on the eyelids and mentions that the eye is very sensitive to bright light. He recalls something scratching the eye a few days before these symptoms started.

Case 7



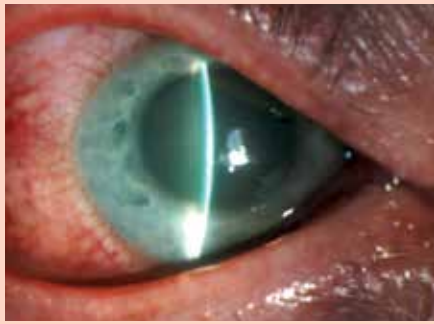
Although not visibly as a red eye, this case of a mildly red eye illustrates why patients may need to be referred if they do not respond to basic eye treatment. This picture is what a specialist would see with fluorescent eye drops in a dark room. A 25 year old patient complains of a scratchy, watery right eye for a couple of days. Her visual acuity is slightly decreased. She has tried chloramphenicol ointment but experienced no improvement. She does recall having had cold sores on her lower lip in the past.

Case 8



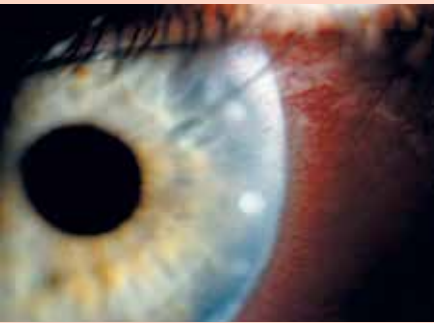A 30 year old male patient presents with a 3 day history of a red, painful, tearing left eye. The visual acuity is moderately reduced on that side and the eye is very sensitive to bright light. He mentions that he experiences pain in the left eye despite keeping only his right eye open in bright light.

Case 9



A 50 year old lady presents with a one day history of a deep, boring pain in her right eye which spreads to the right side of her head. She mentions that she feels nauseous and has vomited twice. The visual acuity in her right eye is severely decreased and the eye is watering constantly. On examination the right cornea appears hazy while the pupil is mid-dilated and does not respond to light. On palpation the eye feels as hard as a golf ball.

Case 10



A 25 year old contact lens wearer presents with a 2 day history of a red right eye which is quite sensitive to light and feels gritty. The eye is watering a lot but her eyelids are not stuck together in the mornings when she wakes up. She has stopped wearing her contact lenses but with spectacles her visual acuity is normal. Examination reveals a diffusely injected eye with small white infiltrates on the peripheral cornea which do not stain with fluorescein.

Answers

Case 1:

**Diagnosis:** Acute bacterial conjunctivitis

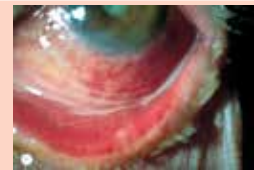
**Pathology:** Unilateral swollen eyelids with diffuse conjunctival injection, mucopurulent discharge and absence of pre-auricular lymph nodes

**Why bacterial?** Diffuse redness of the conjunctiva, obvious mucopurulent discharge, vision not decreased significantly, eyelids stick together in the mornings.

**Why not viral?** Unilateral, discharge not watery, lymph nodes absent

**Why not allergic?** Unilateral, discharge not mucoid, not very itchy

**Treatment:** Often resolves spontaneously but resolution is expedited by topical antibiotics such as chloramphenicol, tobramycin or a fluoroquinolone.



Case 2:

**Diagnosis:** Bilateral viral conjunctivitis

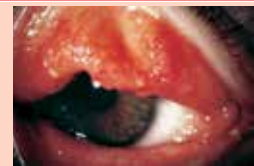**Pathology:** Bilateral viral infection of the conjunctiva causing a follicular reaction and pre-auricular lymphadenopathy

**Why viral?** Both eyes involved after a few days (very contagious), vision intact, watery discharge, pre-auricular lymph nodes swollen

**Why not bacterial?** Discharge not mucopurulent, lymph nodes are swollen

**Why not allergic?** Conjunctival reaction is follicular (not papillary), itching not main complaint, conjunctiva not chemotic.

**Treatment:** Supportive eg artificial tears, cold compresses. Antibiotics not necessary. Take precautions to prevent spread to others



Case 3:

**Diagnosis:** Acute allergic (rhino) conjunctivitis

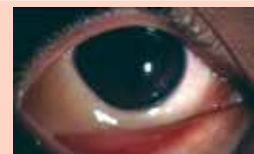**Pathology:** Bilateral allergic conjunctivitis with transient swelling of the eyelids and conjunctiva

**Why allergic?** Bilateral, transient, severe itching, mucoid discharge, sneezing

**Why not bacterial?** Bilateral, discharge not mucopurulent, conjunctiva more swollen (chemotic) than red.

**Why not viral?** Discharge more mucoid (stringy) than watery, no follicular reaction, no swollen lymph nodes

**Treatment:** Ice packs, topical antihistamines or mast cell stabilisers either separately or in a preparation that combines both mechanisms of action such as olopatadine or ketotifen



**Case 4:**

**Diagnosis:** Vernal keratoconjunctivitis

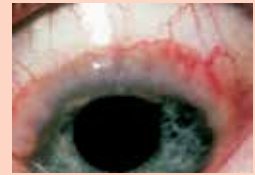**Pathology:** Bilateral, recurrent form of ocular allergy that may lead to giant papillary conjunctivitis, limbal inflammation or both

**Why vernal?** Onset before the age of 10 years, usually in boys, often associated history of asthma or eczema, intense itching with mucoid discharge

**Why not acute allergy?** Onset at typical age, typical sex, becomes chronic, lids and conjunctiva not swollen, limbal inflammation not seen in acute allergy

**Why not conjunctival neoplasm?** Patient too young, intense itching and mucoid discharge present as well as history of atopy

**Treatment:** Oral antihistamines, topical lubricants, antihistamines and mast cell stabilizers. Topical steroids and other immunosuppressive drugs under specialist supervision



**Case 5**

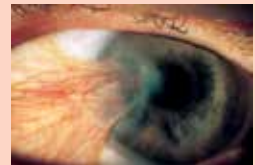**Diagnosis:** Pterygium (Greek: pterýgion =little wing or fin)

**Pathology:** Wing-shaped degeneration of the conjunctiva that grows over the cornea, usually from the nasal side

**Why pterygium?** Conjunctival degeneration, wing-shaped/triangular, crosses the limbus onto the cornea

**Why not pingueculum?** Pingueculum often contains lipid deposits and does not cross the limbus (the border of the iris).

**Treatment:** Initially medical with tear substitutes and mild topical steroid if inflamed. Surgical removal indicated when >2mm over limbus. Prevention also important by limiting exposure to ultraviolet radiation in sunlight eg wearing dark glasses



**Case 6:**

Discussion:

**Diagnosis:** Bacterial corneal ulcer

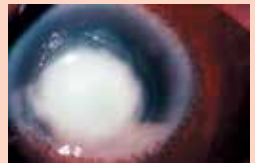**Pathology:** Central corneal ulcer with dense white infiltrate and pus filling about 1/3 of the anterior chamber (hypopyon).

**Why bacterial?** Relatively short history, sticky/mucopurulent discharge, dense central infiltrate without satellite lesions

**Why not fungal?** History too short, absence of satellite lesions

**Why not viral?** Discharge not watery, infiltrate and hypopyon against viral infection of such short duration

**Treatment:** Corneal scrape for laboratory investigations followed by intensive topical antibiotics under specialist supervision. Immediate referral



**Case 7:**

**Diagnosis:** Viral (herpetic) keratitis

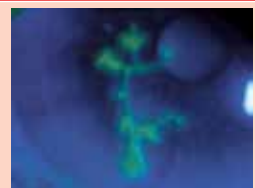
**Pathology:** Branching (dendritic) central corneal ulcer that stains with fluorescein under cobalt blue illumination. Corneal sensation will be decreased if tested.

**Why viral?** Watery discharge, visual acuity reasonably preserved, antibacterial therapy does not work, dendritic ulcer typical of herpes virus, corneal sensation decreased

**Why not bacterial?** Discharge not mucopurulent, visual acuity only slightly decreased, antibacterial therapy ineffective, no obvious infiltrate, corneal sensation decreased

**Why not a healing corneal abrasion?** Healing corneal abrasions may form pseudodendrites which look similar but there should be a history of preceding trauma, the pain would have been quite severe for a day or two, the visual acuity would have been worse initially and the corneal sensation should be intact.

**Treatment:** Acyclovir 3% ointment five times a day for 7 to 10 days. Specialist referral if still no better by then. If ointment not available, oral acyclovir may also be used since it is well secreted into the precorneal tear film



**Case 8**

**Diagnosis:** Acute anterior uveitis

**Pathology:** Inflammation of the iris and ciliary body causing redness to be maximal in the area just behind the limbus (as shown). Inflammation of the ciliary body leads to photophobia i.e. pain when the pupil constricts in response to bright light which happens even when the affected eye is kept closed

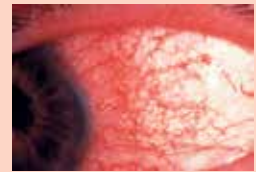**Why anterior uveitis?** Eye tearing, visual acuity reduced, significant photophobia present, pupil constricted, eye tender to touch but does not feel hard.

**Why not keratitis?** No significant discharge, no corneal lesions that stain with fluorescein, redness maximal over the inflamed area just behind the limbus

**Why not conjunctivitis?** No discharge as such, no swollen lymph nodes, visual acuity is decreased

**Why not acute glaucoma?** Cornea is not hazy, pupil in constricted, eye does not feel hard on palpation, patient not nauseous or vomiting

**Treatment:** Patient needs to be investigated for a possible underlying cause. Medical treatment starts with topical steroid drops as well as topical cycloplegic drops but should be overseen by a specialist.



**Case 9**

**Diagnosis:** Acute angle closure glaucoma

**Pathology:** The peripheral iris has occluded the drainage angle of the anterior chamber causing the intraocular pressure to rise rapidly. This causes the cornea to become hazy due to corneal oedema and the pupil becomes mid-dilated and unresponsive to light.

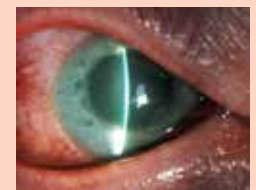**Why acute angle closure glaucoma?** Sudden onset of severe pain that characteristically radiates to the same side of the head; nausea and vomiting in an effort to reduce intraocular pressure by ridding the body of fluid; hazy, swollen cornea; shallow anterior chamber; mid-dilated, unresponsive pupil and eye feels rock hard to touch

**Why not conjunctivitis?** All the reasons given above plus visual acuity is severely decreased

**Why not keratitis?** Cornea is hazy but does not stain with fluorescein; pupil is mid-dilated and unresponsive whereas in keratitis it is usually constricted; watery discharge only

**Why not anterior uveitis?** Pupil is not constricted; the eye feels very hard to touch and the patient is nauseous and has vomited

**Treatment:** Lower the intraocular pressure as quickly as possible by using acetazolamide (intravenously if possible, otherwise orally) and a topical beta-blocker such as timolol or levobunolol; reduce inflammation by using a topical corticosteroid such as dexamethasone and treat pain and nausea with analgesics and anti-emetics as needed. Refer to a specialist as soon as possible for further management



**Case 10**

**Diagnosis:** Immune response keratitis or contact lens-related acute red eye (CLARE)

**Pathology:** Infiltrates develop next to the limbus due an immune reaction against bacterial toxins that collect on contact lenses that are either overworn or not cleaned properly.

**Why CLARE?** History of contact lens wear, watery discharge, peripheral corneal infiltrates that do not stain with fluorescein, moderate discomfort only

**Why not infective bacterial keratitis?** Discharge not mucopurulent, infiltrates do not stain with fluorescein, no hypopyon, visual acuity not decreased and peripheral location of infiltrates against bacterial infection

**Why not Tight lens syndrome?** Conjunctival epithelium does not stain in a ring around the cornea

**Why not acute corneal hypoxia?** Cornea does not show epithelial cysts or macroerosions

**Why not chronic corneal hypoxia?** Cornea does not show peripheral neovascularisation or lipid deposits

**Treatment:** Discontinue contact lens wear until condition completely resolved; review contact lens fit and hygiene; short course of topical antibiotics (to decrease antigens) and topical corticosteroids (to decrease inflammation) preferably under specialist supervision.

