

The red eye

Du Toit N, MBChB, DipOphth(SA), FRCS(Ed), FCOphth(SA), MMed, Senior Lecturer

Van Zyl L, MBChB, DipOphth(SA), FCOphth(SA), Senior Registrar
University of Cape Town; Groote Schuur Hospital

Correspondence to: Nagib Du Toit, e-mail: nagib.dutoit@uct.ac.za

Keywords: red eye, primary health care, conjunctivitis, keratitis, scleritis

Abstract

The red eye is a clinical problem that is encountered regularly in most primary healthcare settings. A wide spectrum of diseases may cause a red eye. Fortunately, most are relatively benign, but many potentially sight-threatening conditions may manifest in a similar way. From the history and examination, the primary care physician must be able to differentiate between features that make primary care treatment possible and high-risk features that necessitate immediate referral. This article includes a discussion on features that distinguish benign from sight-threatening causes of red eye. Unilateral red eye, pain (a deep ache), deep redness, decreased visual acuity and photophobia signify more sinister causes. The red eye has an extensive differential diagnosis. Some of the common causes are conjunctivitis, subconjunctival haemorrhage, episcleritis, scleritis, anterior uveitis and acute glaucoma. Generally, patients who present with red eye can be divided into two groups: those who can be treated at primary care level and those who need secondary or tertiary level care. Other distinguishing features include a pattern to the redness, the type of discharge, the presence of increased lacrimation and photophobia, as well as corneal haze. However, these are not always easily employed as differentiating factors. Therefore, this article lists specific and basic features which can be used to identify the various causes of the red eye.

© Peer reviewed. (Submitted: 2012-08-13. Accepted: 2012-10-04.) © Medpharm

S Afr Fam Pract 2013;55(1):33-40

Introduction

The red eye is a clinical problem that is encountered regularly in most primary healthcare settings. Fortunately, most causes are relatively benign, but many may be potentially sight-threatening.¹ The primary care physician must be able to differentiate between those features that make primary care treatment possible and high-risk features that necessitate immediate referral. The need for an update in this field became apparent following a recent study of primary health eye care knowledge among general practitioners.² This article is the first in a series that will attempt to address this issue.

Approach to the patient with red eye

Taking a history should elicit the laterality, the presence of discomfort or foreign body sensation or itching vs. actual pain, photophobia, visual disturbances, the presence of discharge and the ophthalmologic history associated with the red eye. The examination should focus on visual acuity, the appearance of the conjunctiva and sclera, pupil reactions and shape and palpation for preauricular nodes.³ Fluorescein staining may prove helpful in certain cases.⁴ Features which distinguish the more sinister causes include unilateral red eye, pain (a deep ache), deep redness, decreased visual acuity and photophobia.³

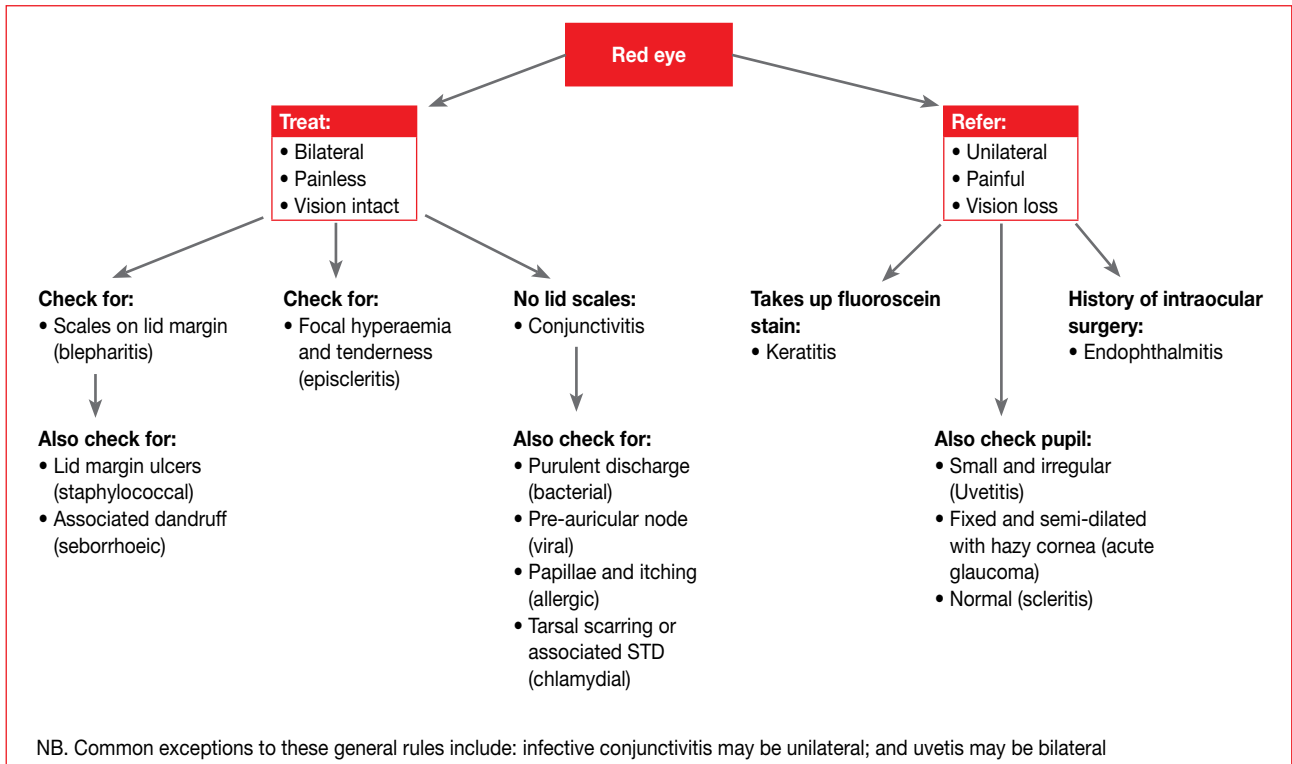
Common causes of red eye are conjunctivitis, subconjunctival haemorrhage, episcleritis, scleritis, anterior uveitis and acute glaucoma.¹ Generally, these can be divided into two groups: those that can be treated at primary care level and those that need secondary or tertiary level care.³ This distinction is broadly based on the symptoms and signs described above. These are listed in Table I.

The more common conditions in these two categories, which will be discussed later, are listed in Table II.

Based on the laterality, pain and level of visual acuity, patients can either be treated or referred. See Figure 1.

Table I: Signs and symptoms that can be used to differentiate between types of red eye

Primary care: red eye	Secondary or tertiary care: red eye
Bilateral (usually)	Unilateral (usually)
Asymptomatic or mild discomfort with scratching, burning and itching	Painful (deep ache)
Redness (bright red)	Redness (deep red)
Normal visual acuity (± intermittent blurring)	Decreased visual acuity
Dryness or wateriness	Photophobia



STD: sexually transmitted disease

Figure 1: Flow chart for the primary care assessment of the red eye

Table II: Clinical conditions in the different categories

Primary care red eye	Secondary (or tertiary) care red eye
Blepharitis	Keratitis
Conjunctivitis	Uveitis and iritis
Episcleritis	Acute scleritis
Pterygium and pingueculum	Acute glaucoma
Subconjunctival haemorrhage	Endophthalmitis
Treatment starts at primary level, but refer or phone for advice as necessary	Refer within 24 hours

There are other distinguishing features, such as the pattern to the redness, the type of discharge and the presence of photophobia, but these are not easily employed as primary differentiating factors. Therefore, the outlined approach in Figure 1 is suggested as a simple way of differentiating between the various causes of the red eye.

Clinical conditions

Blepharitis

Usually, inflammation of the eyelid comprises staphylococcal and seborrhoeic blepharitis. The former is the result of infection of the bases of the eyelashes, while the latter is due to excessive sebaceous secretions from dysfunctional meibomian glands. Both types result in a burning feeling, occasional itching, mildly red eyes and intermittent blurring of vision. Lid margins may be swollen with crusting or “collarettes” at the bases of the eyelashes

in the staphylococcal type (Figure 2), while oily or foamy secretions are visible in the seborrhoeic type. Management includes long-term, twice-daily cleansing using baby shampoo and a cotton bud (or swab) to remove the debris and clear away the secretions. Warm compresses help to combat greasy lids.³ Topical lubricants are used to treat associated tear-film instability.

Conjunctivitis

The most common cause of red eye is conjunctivitis.¹ It manifests as diffuse redness due to inflammation from various causes, which are mostly allergic (acute, vernal and atopic) and infective (viral, bacterial and chlamydial). If there is a history of collagen vascular disease, diuretic or

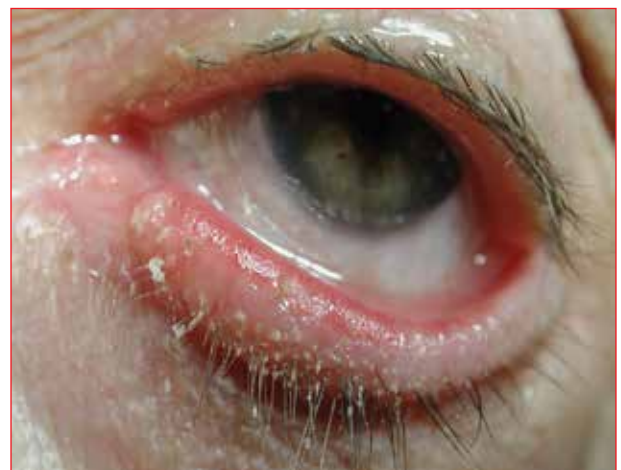

Figure 2: Blepharitis with visible scales and inflamed lid margin

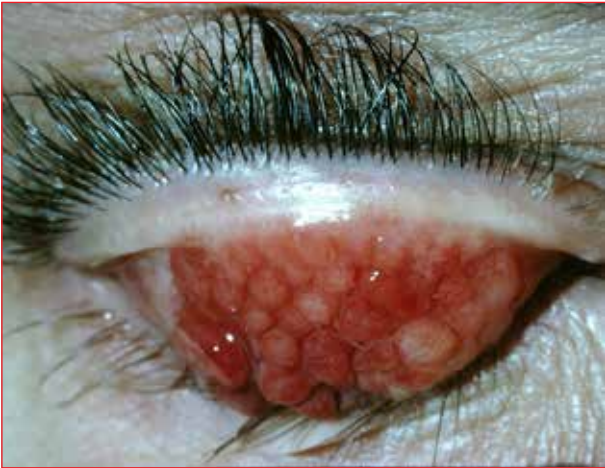

Figure 3: Papillae on tarsal conjunctiva of inverted upper lid

antidepressant use, dry eyes should also be considered as a possible cause of conjunctivitis.⁴

Allergic conjunctivitis (seasonal or perennial) is the most common type of ocular allergy and is often associated with eczema or asthma.⁴ Intense itching is the most prevalent symptom. Discharge may be watery or stringy. The papillae are visible on the tarsal conjunctiva, especially under the upper lid (Figure 3).⁵ Diffuse conjunctival injection can also be caused by dry eyes, contact lenses and over-the-counter eye products.⁶ Management includes removal of the underlying cause as far as possible. Ocular nonsteroidal anti-inflammatory agents (NSAIDs) may reduce discomfort, redness and swelling. Treatment varies according to severity. Topical antihistamines, vasoconstrictors or lubricants are recommended for mild cases and prophylactic sodium chromoglycate (a topical mast-cell stabiliser) for chronic cases. Severe cases should be referred for steroid treatment.¹

Adenovirus is the most common cause of sporadic and epidemic conjunctivitis. Other viral causes include herpes, mumps and rubella. Redness and watery discharge start unilaterally, then become bilateral with associated preauricular lymphadenopathy. Follicles are visible on the conjunctiva, especially in the lower fornix (Figure 4). Viral conjunctivitis is contagious. Patients should be advised to stay at home and to apply symptomatic treatment, such as artificial tears and cold compresses.¹ Adenovirus has been found to have a 95% replication rate at 10 days, which drops to 5% at 16 days.⁴ The patient should be reminded about frequent handwashing and not to share towels. Topical antibiotics are prescribed if it is difficult to differentiate the condition from bacterial conjunctivitis. Adenoviral epidemic conjunctivitis may lead to corneal infiltrates. Elective referral to an ophthalmologist is needed if there is no improvement within 7-10 days⁷ to monitor the development of keratitis.⁸

Usually, bacterial conjunctivitis is caused by *Streptococcus pneumoniae*, *Staphylococcus aureus* and *Haemophilus influenzae*.³ The patient may complain of crusting and difficulty opening the eyelids in the morning. This results from a mucopurulent discharge that causes matting of the

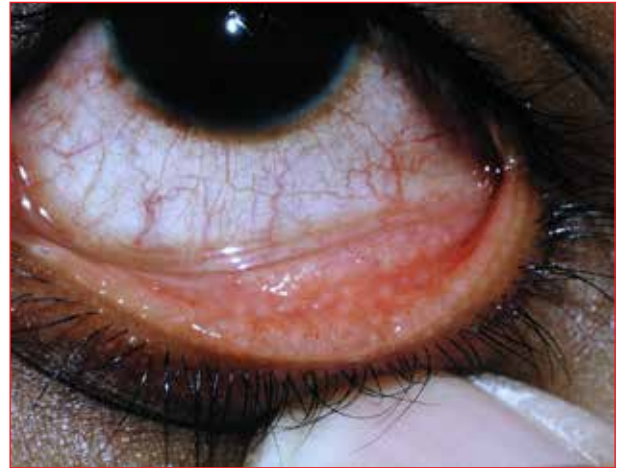

Figure 4: Follicles on lower forniceal conjunctiva

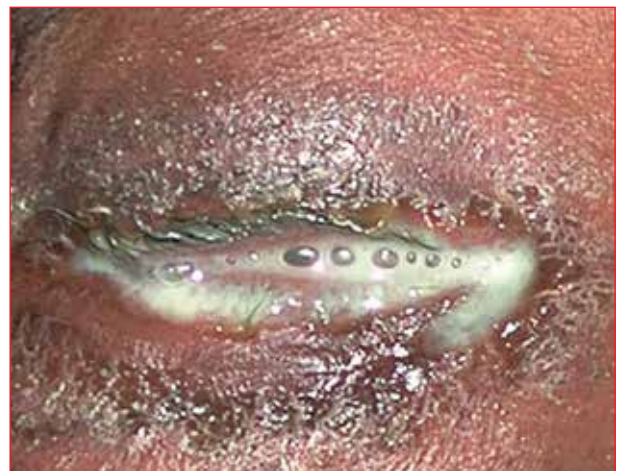

Figure 5: Copious purulent discharge in *Gonococcal conjunctivitis*

lashes.⁵ Treatment consists of broad-spectrum antibiotic drops, e.g. chloramphenicol, for simple cases. Although it is usually a self-limiting disease, treatment shortens its course, reduces the spread from person to person and lowers the risk of sight-threatening corneal ulceration.¹ Generally, *Neisseria gonorrhoeae* is spread by genital contact in sexually-active people, while neonates can acquire it at birth. There is copious, purulent discharge (Figure 5) that reforms quickly after it is wiped away, as well as preauricular lymphadenopathy. It should be treated with saline solution irrigation, ceftriaxone 125 mg intramuscular injection stat and topical ciprofloxacin. Patients must be referred for admission since these bacteria can cause penetration of the intact cornea and cause an abscess.³

Chronic chlamydial infection causes trachoma in the developing world, and acute sexually-transmitted "inclusion" conjunctivitis in young adults and neonates in the developed world. In newborn babies, redness and moderate discharge starts 5-12 days after birth. In adults, the infection can be subacute and is treated by prescribing 1g azithromycin orally stat or 100 mg doxycycline orally twice daily for a week, for both the patient and his or her sexual partners.¹ Topical tetracycline or sulphacetamide ointment two to three times daily for a fortnight is applied

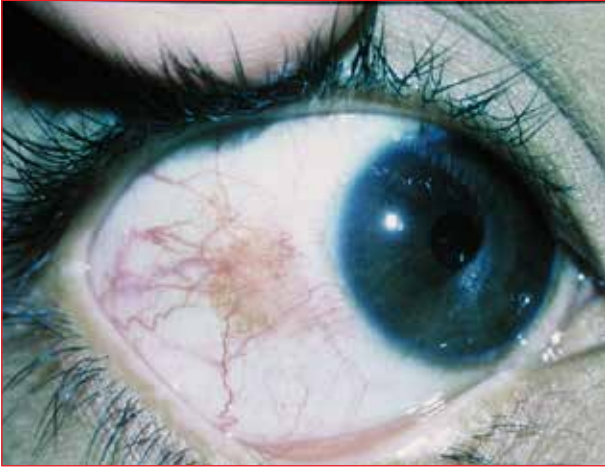

Figure 6: Localised (sectoral) episcleritis

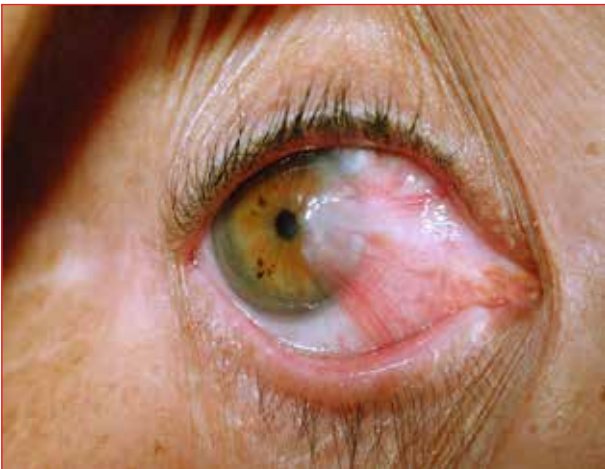


Figure 7: Typical pterygium

to the eyes. Systemic antibiotics are used in addition to topical antibiotics to treat neonatal inclusion conjunctivitis.⁹ Follow-up should be arranged with an ophthalmologist.

Episcleritis

Inflammation of the episcleral layer, situated between the conjunctiva and sclera, is mostly idiopathic in nature and occurs in young adults. Some may have an underlying connective tissue disease, e.g. rheumatoid arthritis, polyarteritis nodosa, systemic lupus erythematosus (SLE), sarcoidosis, Wegener's granulomatosis, gout or syphilis.¹ Symptoms include pricking pain and frequent recurrences. Signs include superficial redness, usually confined to one quadrant (Figure 6) with tenderness on palpation. Normal sclera may be seen between the radially coursing, dilated episcleral vessels which blanch with the application of phenylephrine drops.⁷ Resolution is usually spontaneous. Management consists of topical or systemic NSAIDs in cases in which there is discomfort.

Pterygium and pingueculum

Pterygium and pingueculum are degenerative lesions of the conjunctiva. They are caused by ultraviolet light exposure, dusty environments and hereditary factors.³ Pingueculum is localised to the conjunctiva, but pterygium grows onto the

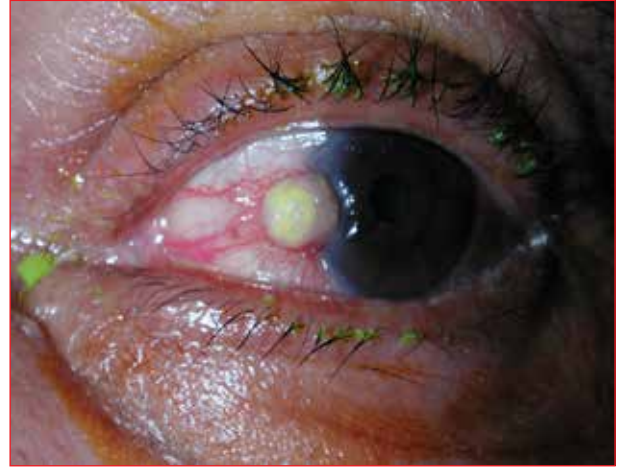

Figure 8: Squamous carcinoma of the conjunctiva in human immunodeficiency virus-positive patient

cornea (Figure 7). Management consists of lubricating drops (artificial tears) for scratchy lesions and topical NSAIDs for inflamed lesions. Surgery is performed if vision is affected or for cosmetic reasons. If the lesion appears atypical (Figure 8), a squamous carcinoma of the conjunctiva in patients with human immunodeficiency virus should be suspected. Referral is necessary.

Subconjunctival haemorrhage

Subconjunctival haemorrhage may be spontaneous or traumatic. It is caused by bleeding of the conjunctival or episcleral vessels.¹⁰ It is common after minor trauma, coughing or valsalva and may also occur spontaneously in hypertensives and patients on aspirin or anticoagulants.³ The patient presents with a painless, red eye with normal acuity. The haemorrhage clears over a period of 2-4 weeks. Prescribing warm compresses and lubricating drops may help to reduce the period of recovery by 1-3 days.¹ Refer the patient if globe rupture is suspected after severe trauma. In such cases, vitreous haemorrhage obscures the view of the fundus.³

Keratitis

Inflammation of the cornea may be caused by viruses, bacteria (including *Pseudomonas*, usually associated with contact lens wear), fungi and protozoa. Immune-related conditions, which include interstitial keratitis, marginal keratitis (caused by staphylococcal hypersensitivity) and peripheral corneal melt from systemic vasculitis (SLE and rheumatoid arthritis), may also result in keratitis.¹ Corneal exposure keratopathy is a consequence of inadequate lid closure, e.g. lagophthalmos after facial nerve palsy and severe proptosis in orbital disease. It also predisposes to infection.

The cornea is avascular and transparent. Inflammation leads to loss of clarity and reduced vision, with reflex hyperaemia in the circumcorneal (limbal) area.³ Any defect in the corneal epithelium predisposes to infection. Keratitis is painful because of the rich sensory nerve supply to the cornea.

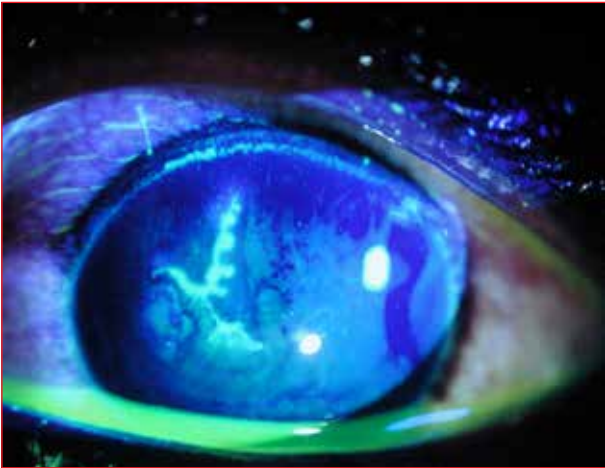


Figure 9: Herpetic dendritic ulcer stained with fluorescein

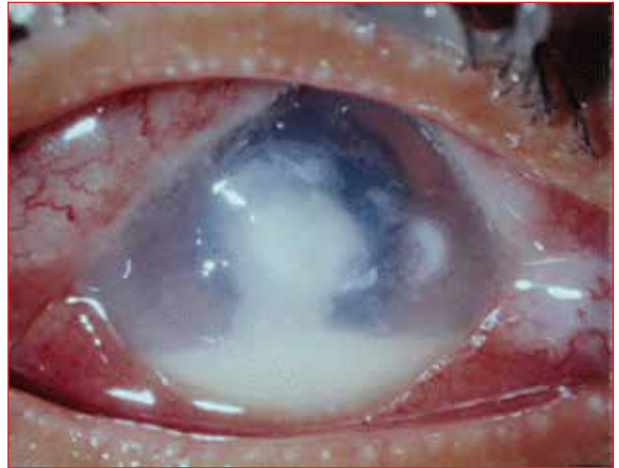


Figure 11: Bacterial corneal ulcer with hypopyon

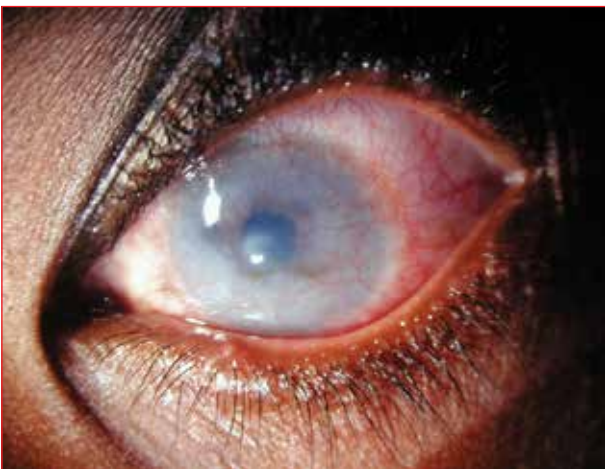


Figure 10: Vascularised, scarred cornea

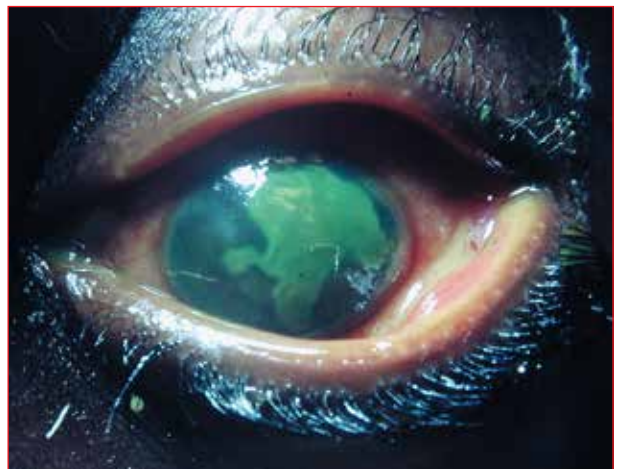


Figure 12: Geographic herpetic ulceration

If herpes simplex virus infection affects the skin and conjunctiva, or is associated with photophobia and decreased vision, viral keratitis should be suspected.¹ Symptoms include a foreign body sensation and increased lacrimation. The corneal epithelial defect (ulcer) has a “dendritic” staining pattern (Figure 9) with fluorescein (a grey line is seen without the stain). There is reduced corneal sensation, while scarring and vascularisation (Figure 10) follow recurrent attacks.³ Herpes zoster (HZV) ophthalmicus accompanied by ocular involvement can occur if HZV is reactivated in the nasociliary branch of the ophthalmic division of the trigeminal nerve. Herpes pustules at the tip of the nose (Hutchinson’s sign) are a classic predictor of ocular involvement.

Bacterial keratitis leads to pain, redness, a purulent discharge and loss of vision. The area of corneal ulceration appears greyish-white and stains with fluorescein. Hypopyon (pus in the anterior chamber) is often present (Figure 11), but is missed unless the lower lid is pulled down during examination. All corneal abscesses can progress rapidly and lead to permanent blindness. Fungal abscesses have a similar appearance and are mostly due to injuries with organic matter, e.g. wood.

All forms of keratitis require ophthalmology referral. Acyclovir ointment is prescribed for herpetic ulcers. Topical steroid drops should never be used, otherwise geographic (large) ulcers (Figure 12) and sometimes melting or perforation from uncontrolled viral proliferation may result. The patient should be started on hourly antibiotic drops before referral for bacterial keratitis.³ In cases of immune interstitial keratitis, the cause (syphilis and tuberculosis) should be treated and then a referral can be made. Corneal exposure requires lubrication, cycloplegic drops and referral.

Uveitis (iritis)

Uveitis denotes inflammation of the uveal tract: iris (iritis), ciliary body (cyclitis) and choroid (choroiditis), which may be acute or chronic. Anterior uveitis, often called iridocyclitis, usually affects young or middle-aged persons. Posterior uveitis includes vitritis, choroiditis and chorioretinitis. Panuveitis describes both anterior and posterior involvement. Causes are generally idiopathic, but approximately half are because of underlying systemic disease, such as tuberculosis, syphilis, sarcoid, toxoplasmosis, cytomegalovirus and seronegative spondyloarthropathies, viz. ankylosing spondylitis, psoriatic

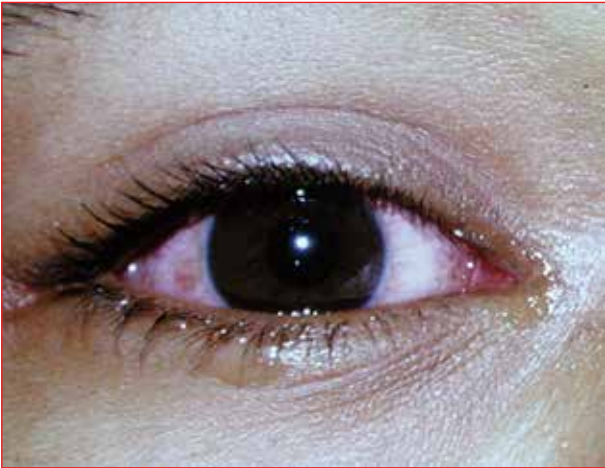

Figure 13: Perilimbal conjunctival injection (redness)

arthritis or inflammatory bowel disease. Traumatic iritis may be seen secondary to a direct blow from a blunt object.¹

Patients present with a painful, red eye with photophobia and reduced vision (there is no redness or pain if it is posterior only).¹ Inflammation is unilateral, but may be bilateral with systemic disease. Signs include a “ciliary flush” (perilimbal) pattern to the redness (Figure 13); keratic precipitates (immune deposits on the corneal endothelium) which make the cornea appear hazy in severe cases; a constricted pupil, often with posterior synechiae (adhesions between the iris and the lens) which cause an irregular shape; and hypopyon in severe cases. The patient may experience direct photophobia when light is shone into the affected eye, as well as consensual photophobia when it is shone in the unaffected eye. This feature is not present with other causes of photophobia.⁴

The patient should be referred for topical corticosteroids in the case of anterior uveitis, and systemic steroids for posterior uveitis. Anticholinergic agents, e.g. atropine and cyclopentolate, produce mydriasis and cycloplegia. This leads to a reduction in pain and photophobia.¹

Scleritis

Scleritis is defined as an inflammation of the sclera that may involve the cornea, adjacent episclera and underlying uvea. Scleritis can be divided into anterior and posterior. Anterior scleritis is subdivided into diffuse, nodular or necrotising. Diffuse anterior scleritis, the most common form, is characterised by extensive scleral oedema and congestion of the scleral vessels (Figure 14).¹ Posterior scleritis may be associated with anterior scleritis or be isolated. Rheumatoid arthritis is the most common causative systemic disease, but many cases are idiopathic. The disease can also be triggered by infection, surgery, malignancy or drugs. Infectious scleritis is more likely in the presence of infectious keratitis.

Usually, scleritis occurs in middle-aged women.¹ Patients experience severe pain that may radiate to the scalp,

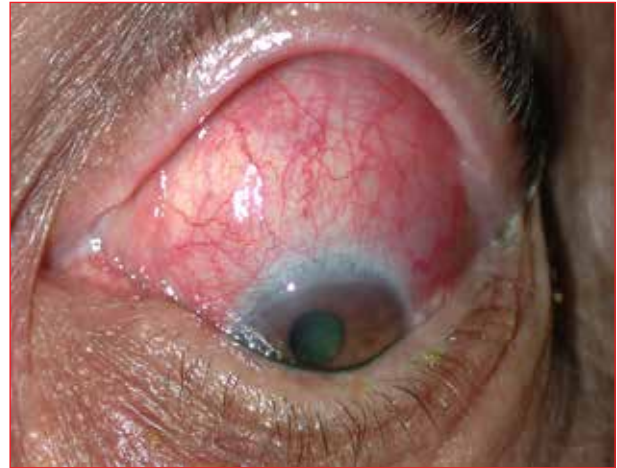

Figure 14: Diffuse scleritis

face and jaw. The severe pain may awaken the patient from sleep or have a significant effect on daily activities. Patients who have posterior scleritis may present with reduced vision with or without pain. Beefy red injection (not blanching with phenylephrine drops) and immobile, irregularly oriented blood vessels on attempted movement with a cotton bud (after instilling topical anaesthetic drops) are definitive signs.³ Management includes investigating for systemic vasculitides and granulomatous diseases, as well as initiation of an oral NSAID and prompt referral to an ophthalmologist.¹

Acute glaucoma

The most common type of acute glaucoma is acute primary angle closure glaucoma. This results from an anatomically predisposed eye, especially in those with South East Asian ancestry and hypermetropia (a short eyeball). It also occurs in patients who are older than 45 years and in those who have been to exposed to sympathomimetics or anticholinergics, e.g. antihistamines or antipsychotics.

When the pupil moves into the mid-dilated position in an eye with a shallow anterior chamber, it may come into contact with the lens (pupil-block), thus hindering and blocking the outflow of aqueous, and resulting in elevated intraocular pressure.⁴ Severe orbital pain follows, often with nausea and vomiting. The patient notices haloes in front of lights from the associated corneal oedema, has a red eye with loss of vision, a hazy cornea, as well as a mid-dilated and non-reactive pupil (Figure 15). The eyeball feels hard on palpation. A shallow anterior chamber is demonstrated by a positive eclipse sign: when a light is shone from the temporal side of the eye, the medial iris is in shadow. Acute attacks may be self-limiting with spontaneous resolution, or may occur repeatedly. These attacks also may be incorrectly diagnosed as migraines.¹¹

Management includes analgesia and antiemetics, aqueous suppressants (acetazolamide 500 mg orally) and immediate referral. Ophthalmologists may use pilocarpine drops to

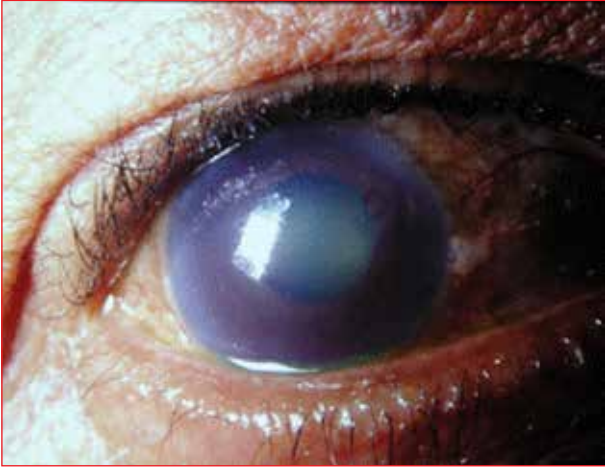


Figure 15: Acute angle-closure glaucoma with mid-dilated pupil and hazy cornea

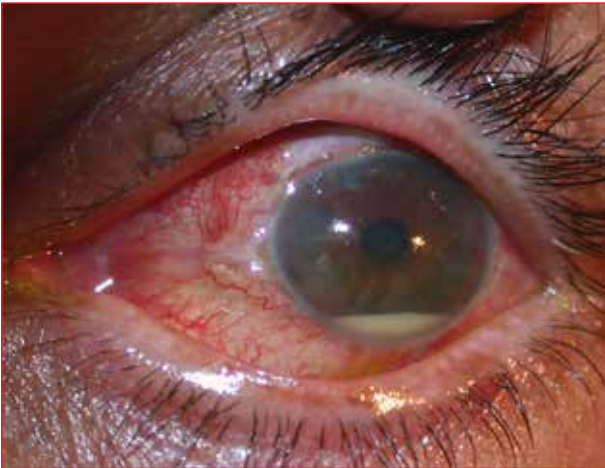


Figure 16: Opacified bleb and hypopyon from endophthalmitis after glaucoma surgery

constrict the pupil, as well as other measures to reopen the angle. A delay in treatment can cause permanent corneal oedema and blindness due to optic nerve damage.

Endophthalmitis

Endophthalmitis refers to infection of the cavities of the eye and may be post-surgical (after cataract, glaucoma or vitreoretinal surgery), post-traumatic (after penetrating eye injuries), or endogenous (most commonly in patients with bacterial endocarditis).³ Usually, a history of recent ocular surgery is elicited, but after glaucoma surgery, infection at the filtration site (Figure 16) may occur years later. Sudden pain in the eye with loss of vision, which is sometimes preceded by minor irritation for a few days, is usual. A red eye with a swollen lid, hypopyon and loss of the red reflex (Figure 17) are important signs. This condition requires immediate referral for intravitreal injection of antibiotics, even in the middle of the night.

Conclusion

Most causes of red eye are benign and self-limiting. Appropriate assessment can identify serious conditions

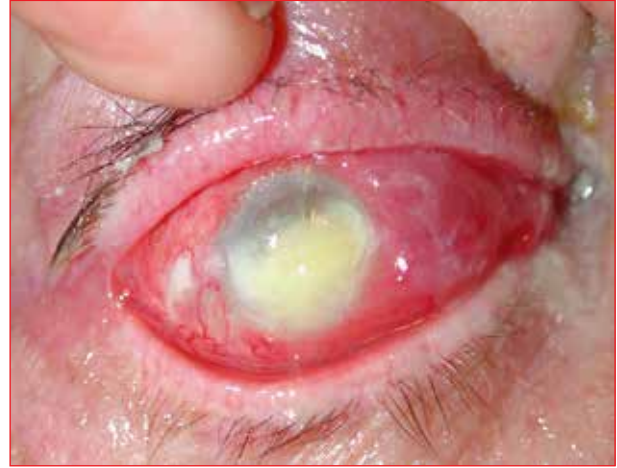

Figure 17: Severe injection with swollen lid and large hypopyon

and prevent significant morbidity. As shown above, the physician should obtain a relevant history, perform a thorough examination and look for warning signs of serious causes that will need referral.

Most cases of red eye are treated supportively. Topical anaesthetic drops should never be prescribed.⁷ Topical steroids must be used only after consultation with an ophthalmologist.² Follow-up by the primary care physician or ophthalmologist needs to be arranged to monitor the effectiveness of treatment and the development of complications.

Acknowledgements

The authors thank the Division of Ophthalmology of the University of Cape Town for permission to use the clinical photographs.

Conflict of interest

There is no conflict of interest to declare.

References

1. Mahmood AR, Narang AT. Diagnosis and management of the acute red eye. *Emerg Med Clin N Am.* 2008;26(1):35-55.
2. Van Zyl LM, Fernandes N, et al. Primary health eye knowledge among general practitioners in the Cape Town metropole. *S Afr Fam Pract.* 2011;53(1):52-55.
3. Du Toit N, Cook C. The red eye and lid. Lecture notes for medical students. Cape Town: Juta, 2009; p. 38-45.
4. Roscoe M, Landis T. How to diagnose the acute red eye with confidence. *JAAPA.* 2006;9(3):24-30.
5. Morrow GL, Abbott RL. Conjunctivitis. *Am Fam Phys.* 1998;57(4):735-746.
6. Hara JH. The red eye: diagnosis and treatment. *Am Fam Phys.* 1996;54(8):2423-2430.
7. Weber CM, Eichenbaum JW. Acute red eye: differentiating viral conjunctivitis from other, less common causes. *Postgrad Med.* 1997;101(5):185-189.
8. Leibowitz HM. The red eye. *N Engl J Med.* 2000;343(5):345-351.
9. Wirbelauer C. Management of the red eye for the primary care physician. *Am J Med.* 2006;119(4):302-306.
10. Rhee DJ, Pyfer MF. The Wills eye manual: office and emergency room diagnosis and treatment of eye disease. 3rd ed. Philadelphia: Lippincott Williams and Wilkins, 1999; p. 130-131.
11. Gordon-Bennett P, Ung T, Stephenson C, Hingorani M. Misdiagnosis of angle closure glaucoma. *Brit Med J.* 2006;333(7579):1157-1158.