

# Easier diagnosis of congenital dislocation of the hip

Solly B. Shochet  
(Dip Pharm) MBChB MPH (HU) DTM & H

Formerly of The Government Health Centre, Baka-el-Garbiyah, Israel, and The Department of Preventive and Social Medicine, Tel Aviv University, Sackler School of Medicine, Tel Aviv, Israel.  
Present Address: Suite 2104, Carlton Centre, Johannesburg 2000.

## SUMMARY

A method that makes possible an easier visual diagnosis of Congenital Dislocation of the Hip is described. It is simple, reliable, rapid and easy to perform. It is based on the observation that in the prone position the normal infant will form, with its heels, when the soles of the feet are held in apposition and approximated to the buttocks, a symmetric curvilinear diamond shaped pattern. A dislocation of the hip will distort the symmetry of the pattern. The test will not detect the unstable hip. It can be used to demonstrate CHD at birth. It simplifies detection of cases missed at birth or those that only appear after birth.

**KEYWORDS:** Hip Dislocation; Diagnosis; Neonatal diseases and abnormalities; infants, newborn.

## INTRODUCTION

**D**ISLOCATION of the hip is the most important asymptomatic congenital abnormality detectable in the newborn period<sup>1</sup>. Of all the postural defects present at birth, only congenital dislocation of the hip (CDH) is not apparent on a visual examination of the infant, and is unique in that it requires a manual examination to detect its presence<sup>2</sup>.

The earlier the diagnosis and the sooner treatment can be instituted, the greater are the chances of obtaining a complete cure, and of lessening the complications of persistent CDH in older children and in adults.

Ortolani<sup>3</sup> in 1936 was the first to establish that manipulation of the newborn infant's hip was the earliest pathognomonic evidence of CDH. Manipulation tests femoral head reducibility into the acetabulum in the already dislocated hip. Barlow<sup>4</sup> in 1962 expressed dissatisfaction with Ortolani's test, in that occasionally the dislocated femoral head slips so smoothly over the lower rim of the acetabulum that no click is elicited and



the hip therefore appears to be normal. Williamson<sup>5</sup> too, felt that there were unexplained problems with Ortolani's test, and whatever the reason for diagnostic failure, lack of reliability of the test is an important problem. Ortolani<sup>6</sup> admitted that his test would be negative in the presence of severe congenital dislocation of the hip.

Barlow<sup>4</sup> described a test, also elicited by manipulation, which differentiated between dislocated and dislocatable hips. Recently Cheetham *et al*<sup>7</sup> have expressed concern about Barlow's test. They feel that if the test is performed too vigorously in the first two days of life, when the hip commonly subluxes freely, damage may result, with persistent dislocation.

Renshaw *et al*<sup>8</sup> consider assessment of the mobility triad to be the most important and reliable physical diagnostic manoeuvre for detecting subtle dysplasia. Most babies are normally born with:

- a. Some degree of hip flexion contractures
- b. A lesser degree of knee flexion contracture, and
- c. A mild hip adduction contracture

collectively known as the mobility triad and are normal, persisting for the first several months of life before being stretched by the active infant.

The importance of assessing the mobility triad is to check asymmetry between the two sides in any or all of the three contractures.

Another very reliable sign, significant at any age, is the apparent short femur sign. With the infant supine the hips and knees are flexed at 90°. The level of the knees should be equal. If one appears shorter, then in the absence of a congenital short femur, the most likely reason is posterior dislocation of the hip.

The test I wish to describe depends on this observation. However, when viewed with the infant in the prone position, this posterior dislocation which in the non-standing infant is also an inferior one<sup>9</sup>, gives rise to an apparent lengthening of the lower limb on the dislocated side.

### INCIDENCE

The incidence of CDH varies throughout the world. It is high among the Lapps, about 40 cases per 1 000 live births<sup>12</sup>, frequent among the Indian tribes of Northern Canada<sup>13</sup>, and found to be 13.3 per 1 000 live births in the USA according to a study of Artz *et al*<sup>14</sup>. In Australia Paterson<sup>11</sup> found an incidence of 5 per 1 000 live births, whereas in Israel, Medalie<sup>16</sup> found 3.1 dislocations per 1 000 live births. In the UK Barlow<sup>4</sup> found an incidence of 1.55 per 1 000 in Manchester, whereas Mitchell<sup>17</sup> found an incidence of 3 per 1 000 in Edinburgh.

It is rare in Canadian Eskimos<sup>13</sup> and according to Edelstein<sup>18</sup> it is extremely rare in the black population of Central and Southern Africa. More recently Pompe van Meerdervoort<sup>19</sup> could find only one case of CDH in 4 500 consecutively born black neonates.

There are no published figures for the South African white population although Beighton<sup>20</sup> believes that it is similar to that of European countries. This has been con-

firmed by Erken<sup>21</sup> who found five cases of unstable hip per 1 000 of white population in the Johannesburg area.

These incidence rates are based on numbers diagnosed at birth or soon after birth; however, there is a significant number of infants who are not diagnosed during this early period. They become the 'missed cases' or at best the 'late diagnosed cases'.

The test is referred to as 'The Heel-to-Buttock' test and as far as I have been able to ascertain, has not been described previously. It is essentially a visual observation and is presented here in the hope that it will prove useful in minimising the number of cases of CDH missed at birth, and that those cases missed or which present themselves later will be picked up early in the newborn period.

### MATERIAL AND METHODS

During the years 1961 — 1980, first as Director of the Government Health Centre at Tira, and from 1978 to 1980 at Baka-et-Garbiyah I was personally responsible for the care of the newborn infants born in the small maternity section attached to the health centre, and also for routine examination of infants and older children attending the Family Health Care clinics of the centres. The health centre provides comprehensive medical care for about 50 000 of Israel's Arab population living in an area known as the Little Triangle.

The findings to be presented here are based exclusively on examination of infants and children born to this section of Israel's population. The heel-to-buttock test for the detection of congenital dislocation of the hip is based on observation made during 1978.

#### The Observation

When placed in the prone position, the legs of most infants at rest assume the frog position. It was observed that if the soles of the feet were placed in apposition and the heels approximated towards the buttocks, a curvilinear, diamond shaped pattern is formed between the heels and the buttocks (**Fig. 3**). This pattern is remarkably constant and is reproducible at all ages in infancy and childhood and can be demonstrated immediately after birth. Constant reproduction of the pattern is dependent on the position of the femur, which, in the prone position, is one of about 70° abduction, forming an angle of 90° with the spinal column.

If this pattern is common to all infants, then any pathological condition of the pelvis and lower limbs should cause distortion of the pattern. The condition thought most likely to cause distortion of the pattern is congenital dislocation of the hip.

With the postero inferior dislocation of the head of the femur, there is 'pseudo lengthening' of the lower limb. This should cause the heel and sole of the foot of the affected side to cross the midline, and when the soles of the feet are placed in apposition and approximated to the buttocks, there should be a distortion of the curvilinear diamond shaped pattern. This has been shown to be the case, and is illustrated in **Figure 6**. The diagnosis of congenital dislocation of the hip was also confirmed by conventional methods of diagnosis, together with radiological examination.



### The Heel-to-Buttock Test

The test is carried out by placing the infant in the prone position. Most newborns and older infants enjoy this position and are usually quiet and relaxed.

Standing on the left side of the infant, the left thigh is gently grasped in the palm of the examiner's left hand. The thumb is placed on the greater trochanter and the little finger on the inner aspect of the knee. The thigh is thus steadied in a position of abduction of approximately  $65^\circ$ .

The angle between the spinal column and a line running through the inferior angle of the patella to just below the curvature of the buttocks should be as near as possible to  $90^\circ$ . Grasping the left foot in the right hand, the heel is approximated to the buttock (Fig. 1). In the non-dislocated hip, the sole of the foot will not cross the midline and will form, with the buttock, the one side of the diamond.

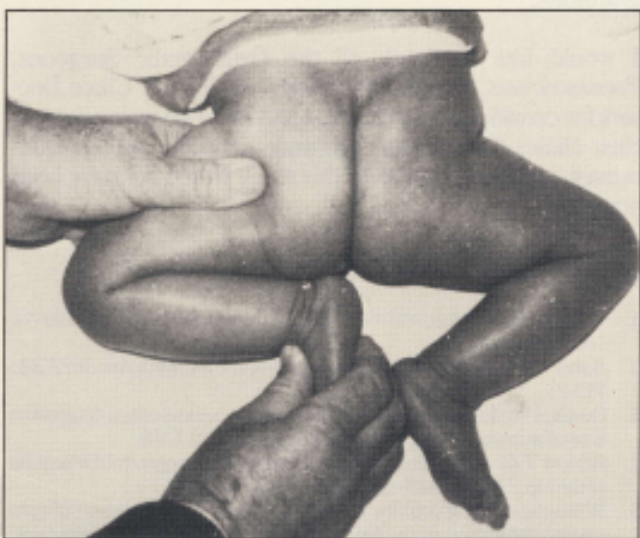


Fig 1 Heel-to-Buttock Test; normal left side.

The procedure is repeated from the right side of the infant, where the same pattern should be formed in the non-dislocated right hip (Fig. 2). The soles of the infant's feet are next placed in apposition and held in the left hand. The pelvis is held steady with the thighs still in abduction as previously

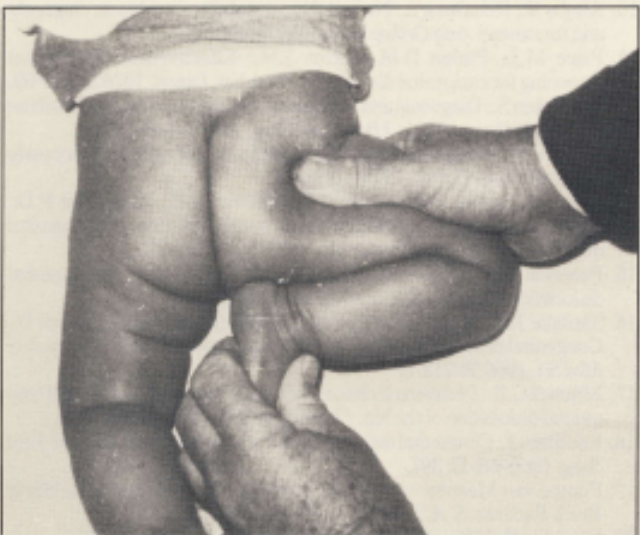


Fig 2 Heel-to-Buttock Test; normal right side.

described, by placing the right hand across the lower part of the infant's back. This will reconfirm that both hips are not dislocated, by illustrating the symmetrical diamond shape formed by the heels and buttocks (Fig. 3).

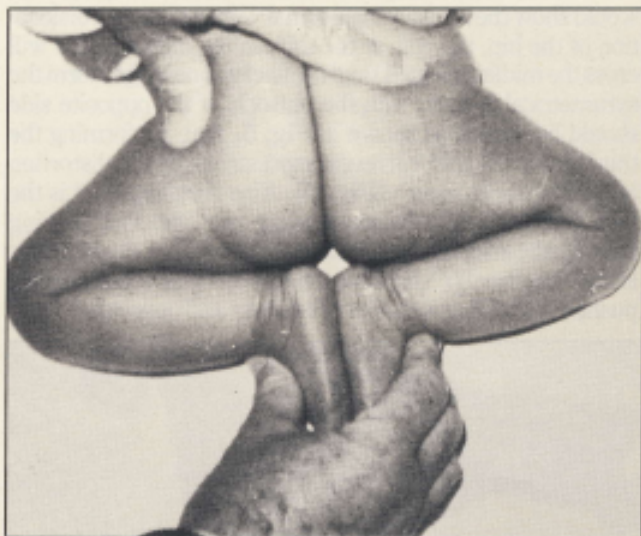


Fig 3 Curvilinear Diamond Shaped Pattern; normal finding with no dislocation.

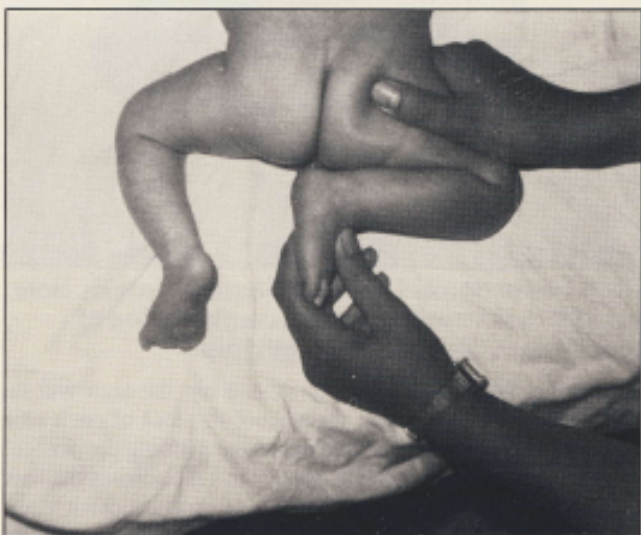

Fig 4 Heel-to-Buttock Test; abnormal. Sole of right foot crosses the midline, dislocation of right hip.

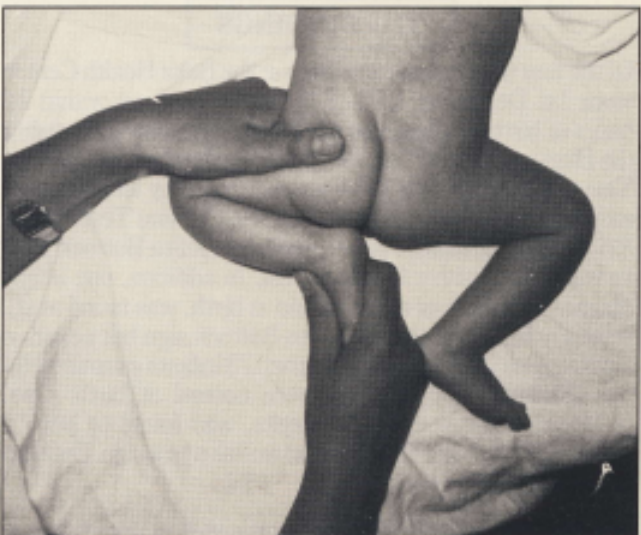
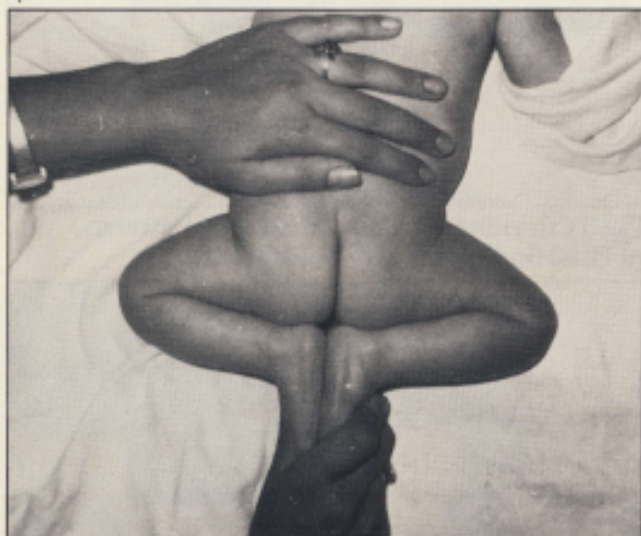
Fig 5 Heel-to-Buttock Test; normal left side.



Care should be taken that the hips on each side are not abducted further than about 60–70°, as this would be equivalent to performing Ortolani's test and would thus reduce a dislocation, if present, and the heel-to-buttock test would show the hip as being normal. When there is a dislocation of the hip, the sole of the foot on the affected side will cross the midline (Fig. 4) and the heel will no longer form the symmetrical pattern with the buttock. If the opposite side should be normal as shown in Fig. 5, then performing the third part of the test will reveal most strikingly the distortion of the diamond pattern (Fig. 6). Also very apparent is the fact that the angle between spine and the line passing through the inferior angle of the patella to below the buttocks is now less than 90°, because the sole of the affected side has pushed that of the normal side laterally and upwards.



**Fig 6 Distortion of Diamond Shaped Pattern. Sole of right foot crosses midline; confirmation of diagnosis of dislocation of right hip.**

If there is bilateral dislocation of the hip the sign will be positive for each side, i.e. the sole of the foot of each side being tested will cross the midline on performing the heel-to-buttock test. When placed in apposition, the soles of the feet will meet centrally but quite distally and on attempting to approximate the heels towards the buttocks, the heels will rise above the level of the buttocks.

### THE FINDINGS

Of the first thousand infants born at the Baka Health Centre since 1st December 1978, 827 were examined within 24 hours of birth and again on the fourth day after birth, using the Heel-to-Buttock Test as well as the Ortolani and Barlow Tests. The remaining 173 were examined by an additional member of the staff who used only the Ortolani Test. Of the 827, four were found to have a positive Heel-to-Buttock Test as well as a positive Ortolani Test. In addition, one infant diagnosed as having a normal hip at birth, was found at six weeks to have a positive Heel-to-Buttock sign but negative Ortolani and Barlow Tests. Of the 173 infants examined by the Ortolani Test only, all were normal at birth. One, however, when seen at six weeks, was found to have a positive Heel-to-Buttock Test, as well as a jerk sign. Dislocation was confirmed on X-ray.

The test was extensively used in the well infant clinics. A distressing number of cases were found which had been

missed on earlier examination. The findings suggest that in spite of improved awareness of CDH cases are being missed as frequently as they are being diagnosed at birth. Other investigators<sup>5, 10, 11</sup> have also found this to be true.

### CONCLUSIONS

It is believed that the Heel-to-Buttock Test will prove a helpful additional clinical sign in the early detection of CDH. It will not detect the unstable nor the dislocatable hip.

The test is easy to perform and reliable if performed correctly. It can be taught to all para-medical staff with no danger of injury to the hip joint as it does not demand full abduction. It is believed to increase the sensitivity of the neonatal examination and thus the effectiveness of the preventive programme. It is also essential to make all medical and paramedical personnel more aware of the condition by educational programmes.

I would like to thank all the Orthopaedic Surgeons, Paediatricians, Family Physicians and Family Clinic Doctors for considering that the test had merit by trying it out in their clinics. My deepest gratitude to all the public health nurses, without whose help this study would not have been possible.

### REFERENCES

1. Valman H.B.: Congenital dislocation of the hip. *Dev Med Child Neurol*, 1978;20:103-4.
2. Asher M.A.: Orthopaedic screening. *Pediatr Clin North Am*, 1977;24: 713-21.
3. Ortolani M.: La lussazione congenita dell'ancuovi criteri diagnostici E profilattico-correttivi, Bologna, Editore Capelli, 1948.
4. Barlow T.G.: Early diagnosis and treatment of congenital dislocation of the hip. *J Bone Joint Surg*, 1962;44-B: 292-301.
5. Williamson J.: Difficulties in early diagnosis and treatment of congenital dislocation of the hip in Northern Ireland. *J Bone Joint Surg*, 1972;64-B: 15-17.
6. Ortolani M.: Discussion on congenital dislocation of the hip. *J Bone Joint Surg*, 1961;43-A: 284-5.
7. Cheetham C.H., Garrow D.H., Tarin P., Medhurst A.W.J.: Congenital dislocation of the hip. *Br. Med J.*, 1983; 286:227.
8. Renshaw T.S., Cary J.M., Gage J.R.: An Update: Detection of Congenital Dysplasia of the Hip. *Conn. Med.*, July 1981, 45(7): 427-31.
9. Browne D.: The treatment of congenital dislocation of the hip. *Proc R Soc Med*, 1948; 14: 388-91.
10. Almby B., Rehnberg L.: Neonatal hip instability, incidence, diagnosis and treatment. *Acta Orthop Scand*, 1977;48: 642-9.
11. Place M.J., Parkin D.M., Fitton J.M.: Effectiveness of neonatal screening for congenital dislocation of the hip. *Lancet*, 1978;2: 249-50.
12. von Rosen S.: Diagnosis and treatment of congenital dislocation of the hip joint in the newborn. *J Bone Joint Surg*, 1962;44-B: 284-91.
13. Ortolani M.: Congenital hip dysplasia in the light of early and very early diagnosis. *Clin Orthop*, 1976; 119:6-10.
14. Artz J.D., Levine D.M., Lam W.N., Salavati E.P., Wilson Jnr P.D.: Neonatal diagnosis, treatment and related factors of congenital dislocation of the hip. *Clin Orthop*, 1975; 110: 112-36.
15. Paterson D.C.: The early diagnosis and treatment of congenital dislocation of the hip. *Clin Orthop* 1976; 119: 28-38.
16. Medalie J.H., Makin M., Alkalay E., Yoffe J., Cochavi Z., Erlich D.: Congenital dislocation of the hip. 1. Retrospective incidence study. *Isr J Med Sci*, 1966;2: 212-7.
17. Mitchell G.P.: Problems in the early diagnosis and management of congenital dislocation of the hip. *J Bone Joint Surg*, 1972;54-B: 4-12.
18. Edelstein J.: Congenital dislocation of the hip in the Bantu. *J Bone Joint Surg*, 1966;48-B: 397.
19. Pompe van Meerdervoort H.F.: Congenital Dislocation of the Hip in Black Patients. *S. Afr. Med. J.*, 1974;48: 2436.
20. Beighton B.: 1983: Personal Communication.
21. Erken E.H.W.: 1983: Personal Communication.