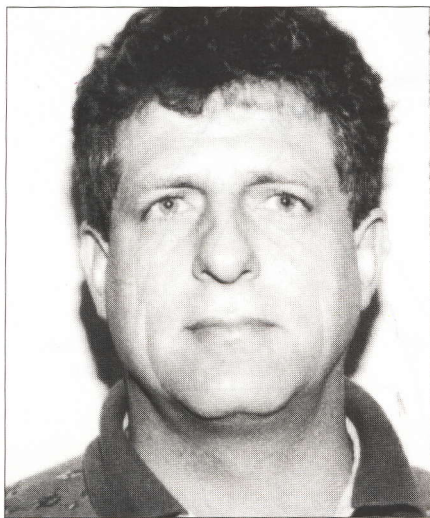


## The Practical Approach to Shoulder Pain: The "Rule of Five"

— Dr JF de Beer, Dr MA de Beer



Dr JF de Beer (Cape Town) above  
Dr MA de Beer (Pretoria) below



### Curriculum Vitae

Drs Joe de Beer and Thys de Beer are Orthopaedic Surgeons in private practice (Cape Town and Pretoria respectively). They are specifically interested in shoulder problems and they are keen on shoulder arthroscopy as well as open (conventional) surgery. They are honorary lecturers to the Sports Science Departments of UCT and UP.

### Summary:

*A practical guide to help GPs in dealing with shoulder problems most frequently encountered in their surgeries. Groupings of 5 were developed which will help them to remember most aspects and a series of figures is given which illustrate certain techniques.*

*S Afr Fam Pract 1993;14:491-6*

### KEYWORDS:

Physicians, Family; Shoulder Joint.

This paper is intended to be a practical guide to deal with those shoulder problems that are encountered most commonly in practice.

The authors have devised the rule of 5 to be applied for memorising most aspects of shoulder problems.

### Anatomy:

There are 5 mobile entities that play an important role in the shoulder:

#### 1. Gleno-humeral joint:

This is usually referred to as the shoulder joint and consists of the head of the humerus articulating with the concave glenoid fossa. This fossa is deepened by the labrum which adds to the stability of the joint. The joint is further stabilised by the gleno-humeral ligaments, the capsule and the tendon of the long head of the biceps.

#### 2. Subacromial articulation: (Figure 1)

The rotator cuff consisting of subscapularis, the supra spinatus, the infra spinatus and teres minor muscles cover the head of the humerus. Especially the supra spinatus muscle glides in this subacromial space also referred to as the coraco acromial arch. It has to be remembered that this space lies superior to the shoulder capsule and is extra-articular.

#### 3. Acromio-clavicular joint:

The articulation between the acromion and clavicle is stabilised by the acromio-clavicular ligaments. This joint has its own intra-articular meniscus.

#### 4. Sterno-clavicular joint:

This is also a fairly rigid joint where the clavicle articulates with the sternum at its medial end.

#### 5. Scapulo-costal joint:

During shoulder movements there is a large degree of motion of the scapula on the ribs, and this has to be taken into account when measuring shoulder motion.

The 5 common conditions that are seen in practice are:

#### 1. Rotator cuff impingement (with or without tears):

This is impingement on the rotator cuff by the previously mentioned coraco-acromial arch: The main offender is usually the acromion itself with the coraco-acromial ligament and AC joint also potential impingement factors. The rotator cuff

... Shoulder Pain

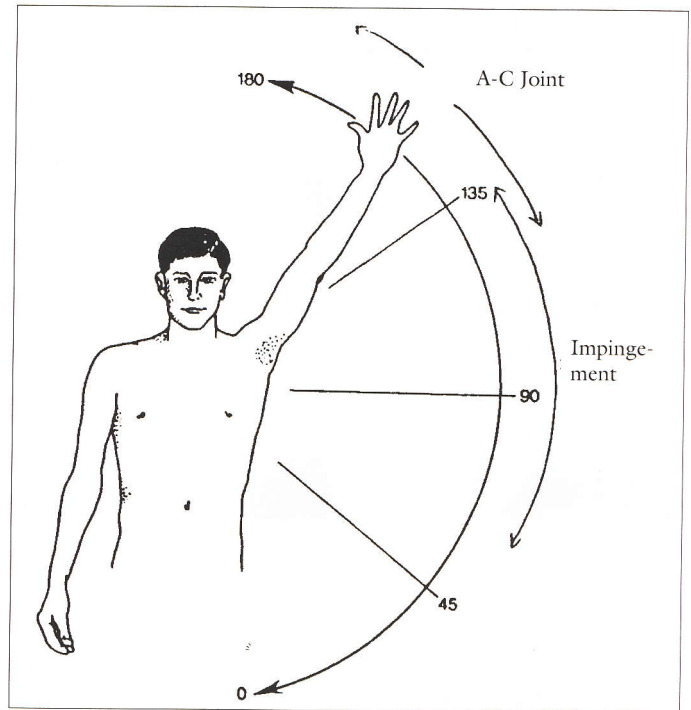
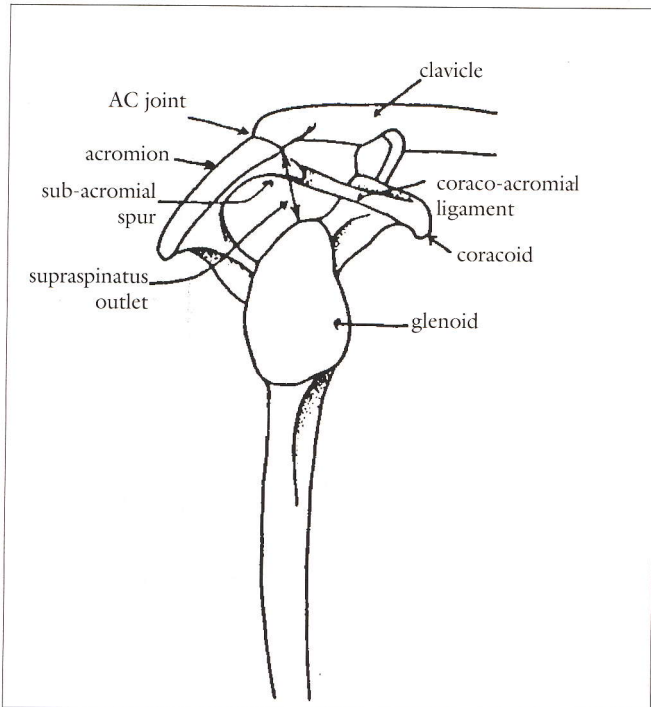


Figure 1. Spinatus outlet (Subcromial space)

Figure 2. Painful Arc

impingement syndrome can of course be associated with tears of the rotator cuff.

2. *Acromio-clavicular joint problems:*

These are usually either degeneration or instability of this joint.

3. *Gleno-humeral instabilities:*

Shoulder instability is mostly related to previous injury that has resulted in detachment of the labro-ligamentous complex (Bankart lesion) or chronic ligamentous laxity (as seen in multi-directional instability).

4. *Gleno-humeral arthritis:*

Arthritis of the shoulder joint results in loss of cartilage from the joint surfaces as mostly seen in osteo-

arthritis, rheumatoid arthritis and some of the crystal arthropathies.

5. *Frozen shoulder:*

Also referred to as "adhesive capsulitis" is regarded as an idiopathic condition with a natural history that leads to spontaneous resolution after many months.

**Clinical Evaluation:**

A diagnosis of shoulder pain can usually be made by taking a history and clinical and radiological evaluation.

**History (5 points):**

There are 5 important points when taking the history in a shoulder complaint:

1. *Previous trauma* (either to the shoulder or the neck).

2. *Painful arc* – ask the patient where in the arc of elevation the pain occurs (Figure 2). In impingement the pain typically occurs between 40 degrees to 120 degrees whereas in AC-joint problems it occurs above 120 degrees.

3. *Painful position* – ask the patient specifically in which position of the arm and which specific activity most of the pain occurs.

Typically elevating the arm to the side or to the front causes pain in impingement. In the athlete with a dislocating or subluxing shoulder or certain labral tears there is often pain in the abducted and externally

## ... Shoulder Pain

rotated position like in throwing or moving the arm in overhead activities like swimming, bowling, etc.

4. *Night Pain* – Does the pain wake the patient up when lying on the shoulder – this typically occurs with impingement or AC-joint problems.

5. *Instability/clicking* – Does the shoulder feel unstable, or does it slip out in certain positions?

## Clinical Examinations:

(5 Points)

When examining the shoulder there are again 5 main aspects to look for:

1. *Muscle atrophy:*

Look specifically at deltoid, supra spinatus and infra-spinatus. The latter 2 muscles can be clearly seen

above and below the scapular spine. Atrophy of these can often signify a rotator cuff tear, or neurologic condition.

2. *Localisation of tenderness:*

Palpate the AC-joint, deltoid, rotator cuff, bicipital groove and surrounding structures.

3. *Range of motion:*

The range of motion (active and passive) should be checked as well as noted where pain occurs, (as in the painful arc). Check specifically for the range of passive abduction by stabilising the scapula with one hand and raising the arm with the other hand. Check for passive external rotation by having the elbow at the side and with the forearm flexed to 90° rotate the forearm externally to check the range. Internal rotation is

checked by noting how far the thumb can reach up the back and is noted as “thumb to L1, T4” or whatever level.

Active range of motion – when checking active range of motion take note of the power of both abduction and external rotation, as weakness of either could indicate a rotator cuff tear.

4. *The impingement sign:*

This is a very valuable test to detect rotator cuff impingement under the acromion and is done as follows:

With one hand stabilise the acromion (and scapula) and with the other hand passively abduct the arm so as to “squeeze” the rotator cuff between the humeral head and the acromion. (Figure 3)

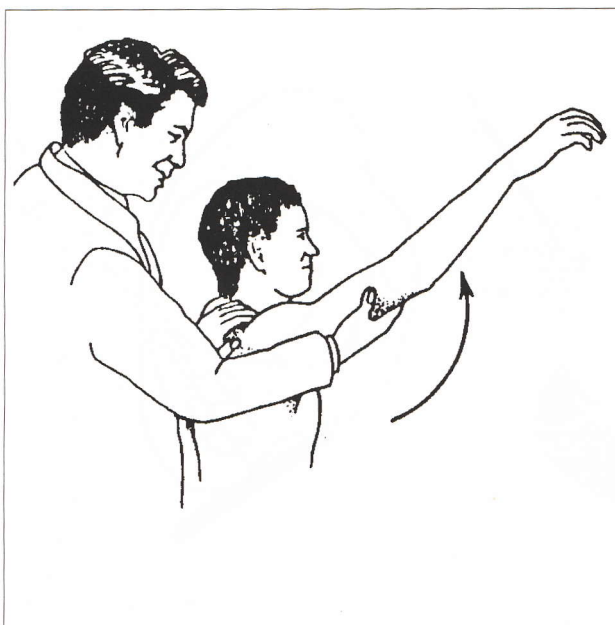


Figure 3. The Impingement Sign

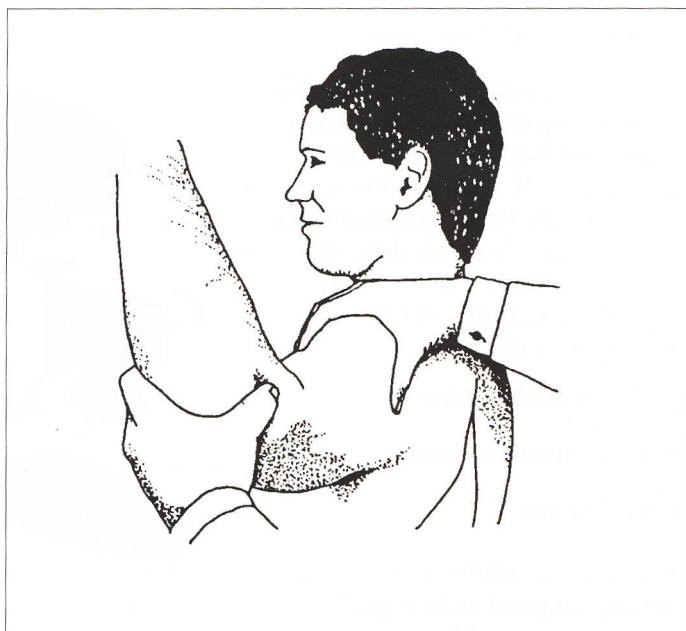

Figure 4. Apprehension Test

... Shoulder Pain




Figure 5. Shape of the Acromion

5. *The Apprehension Test* – passively abduct and externally rotate the shoulder (into the “hands-up” position) – this will lead to pain and/or apprehension especially with labral lesions resulting in instability. (Figure 4).

Radiology (5 views):

There are 5 important views:

1. *Supra spinatus outlet view* – this is the most important view to evaluate rotator cuff impingement as the shape and angle of the acromion (Figure 5) and the subacromial space can be evaluated on this view. It is done by shooting an X-ray in the plane of the scapula and 15° downwards (Figure 6).

2. *AP (internal rotation).*

3. *AP (external rotation).*

4. *Axillary view.*

5. *10 degrees oblique AC view* – this view gives a good indication of degeneration or subluxation of this joint.

There are 5 points that are characteristic in pointing to the diagnosis in each of the 5 common conditions:

Impingement:

1. Painful arc:  
The patient typically complains of pain when elevating the arm to the front or to the side and also has pain when reaching back eg putting the arm into the second sleeve of a jacket.
2. Cannot sleep on the shoulder.
3. There is usually tenderness over the rotator cuff.
4. The impingement sign is usually positive. (Figure 3).
5. The supra spinatus outlet view

shows a narrowed outlet on X-ray, (Figure 6) – this is usually associated with an abnormally shaped acromion – either type 2 or 3 (Figure 5).

Instability:

1. There is usually a history of previous trauma or sometimes chronic overuse as in overhead sports.
2. There is often a history of “popping/clicking”.
3. The patient is often aware of recurrent dislocations/subluxation.
4. There is a positive apprehension test.
5. There may be a Hill-sachs lesion on the axillary X-ray (Hill-sachs lesion is a postero-lateral defect on the humeral head secondary to the recurrent dislocation).

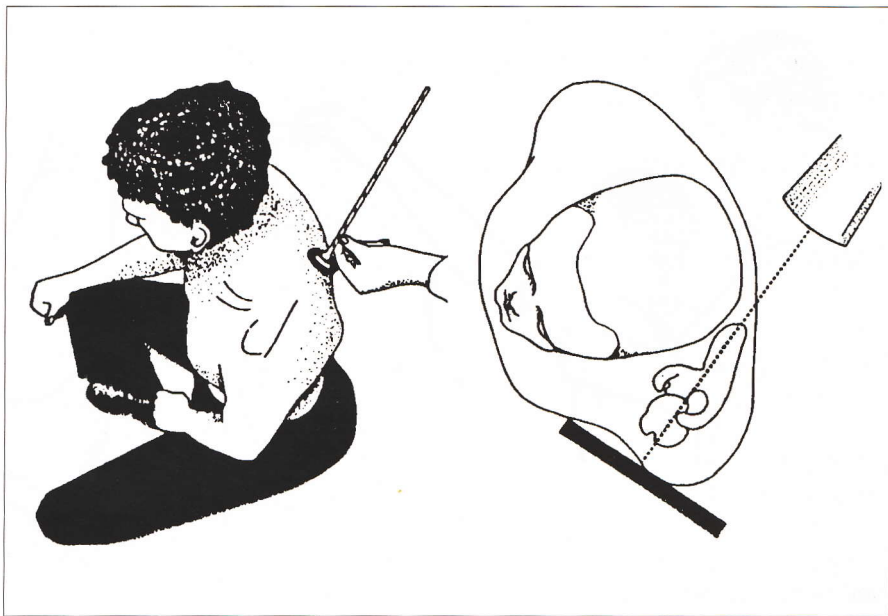


Figure 6. Supraspinatus outlet view

... Shoulder Pain

**Frozen Shoulder:**

1. There is often an insidious onset.
2. There is continuous pain present.
3. Women between 45 and 55 years of age are mostly affected.
4. All movements are restricted and painful – characteristically there is a marked decrease in passive range of motion for abduction, external rotation and internal rotation.
5. X-rays show generalised osteopenia.

**AC-Joint Problems:**

1. There is often a history of previous trauma.
2. Tenderness on pressure over the AC-Joint is characteristic.
3. Pain in the higher degree of the painful arc and also when adducting the elbow across the body.
4. The AC-joint is often unstable on palpation.
5. X-rays may show degeneration or subluxation of the AC-joint.

**Gleno-Humeral Arthritis:**

1. Slow onset.
2. Other joints may be affected by the arthritic condition.
3. A good but painful range of motion may be present.
4. Blood examination might be

**Rule of Five – at a Glance**

**Anatomy:**

- 1) Gleno-humeral joint
- 2) Sub-acromial articulation
- 3) AC-joint
- 4) SC-joint
- 5) Scapulo costal joint

**Common conditions**

- 1) Rotator cuff impingement
- 2) AC-joint problems
- 3) Instabilities
- 4) Arthritis
- 5) Frozen shoulder

**General History**

- 1) Previous trauma
- 2) Painful arc
- 3) Painful position of arm
- 4) Night pain
- 5) Instability/clicking

**Examination:**

- 1) Muscle atrophy
- 2) Tenderness (localised)
- 3) Range of motion
- 4) Impingement sign
- 5) Apprehension test

**X-rays**

- 1) Outlet view
- 2) AP int rotation
- 3) AP ext rotation
- 4) Axillary view
- 5) AC-joint view

**Instability:**

- 1) Previous trauma
- 2) Popping/clicking
- 3) Recurrent dislocation
- 4) Apprehension sign (+)
- 5) Hill-sachs lesion on X-ray.

**Frozen Shoulder:**

- 1) Insidious onset
- 2) Continuous pain
- 3) Women 45 to 55
- 4) All movements restricted
- 5) X-ray: general osteopaenia

**AC-Joint problems:**

- 1) Previous trauma
- 2) Tenderness over AC-joint
- 3) Pain in higher degree of arc
- 4) Instability of AC-joint
- 5) X-ray.

**Cervical Spine:**

- 1) One out of five cases with shoulder pain referred from neck.

**Impingement:**

- 1) Painful arc
- 2) Cannot sleep on shoulder
- 3) Tenderness over rotator cuff
- 4) Impingement sign (+)
- 5) Outlet view

## ... Shoulder Pain

positive for other types of arthritis like rheumatoid or gout.

5. X-rays show osteopenia, osteophytes and a decreased joint space.

### Cervical Spine:

Problems in the cervical spine may cause referred pain to the shoulder and the rule of 5 applies again:

In one out of 5 cases (20%) the shoulder pain can be referred from the neck.

Treatment of each of the above conditions:

#### *Impingement:*

1. NSAIDs
2. Rest: Avoid the impingement position (a hairdresser may for example drop her elbow while working).
3. Subacromial steroid injection.
4. If improvement – physiotherapy.
5. Rehabilitation: What is especially important is exercising the internal and external rotators of the shoulder and also stretching the posterior capsule.

#### *Instabilities:*

1. Acute shoulder dislocation: reduce and refer.
2. Subtle instabilities – refer.

#### *Frozen Shoulder:*

1. NSAID
2. Physiotherapy.

3. Encourage home stretching with the aid of devices like rubber bands, pulleys etc.

4. In the very resistant case manipulation under anaesthesia may be indicated.

#### *AC-Joint:*

1. Conservative – Local steroid injections may be of great help.
2. Physiotherapy is of little value in AC-joint arthritis.
3. Surgery can be of value to the resistant case either by excising the lateral 1cm of the clavicle for degeneration or reconstructing the AC-joint for chronic subluxation.

#### *Gleno-humeral Arthritis*

1. NSAID.
2. Physiotherapy.
3. If no response – Arthroscopic synovectomy especially for the rheumatoid and crystal synovitis cases.
4. Total joint replacement for the severe case is of great value.