


Wound management using semi-occlusive dressing

U Mennen MBChB(Pret), FRCS (Glasg), FRCS (Edin), FCS(SA)(Orth), MMed (Orth), MD(Orth)(Pret).

AMJ Wiese BNurs (Stell), Dip Obs, D Orth Nurs (SANC), BMed Sci (Pret)

D Boomker ND Micro (Pret), NDMTL Micro (PE), ND Clin Tech Andr. (Pret) BA (Unisa)



Curriculum Vitae

Ulrich qualified at Pretoria (MB ChB) in 1970 and received the FRCS in Glasgow in 1978 and Edinburgh (1978), and in 1983 he received the MD (Orthopaedics) from the University of Pretoria. Ulrich has worked in various countries (Germany, England, United States) but is currently professor and Head of the Department of Hand and Microsurgery at Medunsa and has a limited private practice in the Jacaranda Hospital. He is married to Johanna and they have three children.

U Mennen
Dept of Hand and Microsurgery
P O Box 186
Medunsa
0204

Summary

A great deal of confusion still surrounds the aspects of wound dressing, wound contamination, colonization, infection and the role of sterility, anti-biotics and the type of dressing to be used. This article deals with these issues but mainly describes (and illustrates) the method of applying semi-occlusive dressings (especially Opsite), and then gives the outcome of about 800 wounds treated in this way (moist wound healing). It highlights the amazing healing ability of the body in an optimal environment, which semi-occlusive dressings do create.

Introduction

Wound management remains a controversial subject. A great deal of confusion exists regarding wound contamination, colonisation, infection and the role of sterility, antiseptics, antibiotics and the type of dressing.

During the past five years we have pursued the moist wound management philosophy which promotes the concept that in an optimal environment the body has an amazing healing ability. This philosophy states that all (non-surgical) wounds are contaminated by organisms. This could sometimes lead to infection but mostly to colonisation. Colonisation of wounds is an integral part of the healing process. Exudate is normally produced by all wounds and consists of and contains multiple elements

S Afr Fam Pract

1995;16:328-335

KEYWORDS

Wounds and Injuries;

Wound Healing;

Semi-Permeable

Dressings.

Wound Management

(macrophages, growth factors, glucose, micro-organisms, etc). Essential for wound healing, all these must be in a delicate balance with one another. By sealing off a wound with a membrane which is permeable to O₂ but impermeable to micro-organisms and water, an equilibrium is created which enhances an environment optimal for healing. Dressing the wound with gauze or treating it with chemicals like antiseptics or antibiotics, disturbs the equilibrium for natural healing. When infection sets in the equilibrium becomes more favourable for micro-organisms which spread beyond the confines of the wound. This could happen in wounds which are super-infected, immuno-compromised patients or in patients with a low resistance. Only in such cases do antibiotics and antiseptics have a role in the treatment as they help restore the equilibrium.

A variety of semi-occlusive dressings is available. From extensive usage and research it is our contention that "Opsite" (Smith and Nephew) not only allows for easy application, but it proved to give the lowest incidence of complications such as skin reactions. We have published our findings on the use of "Opsite" on various types of wounds and we have found that it produces the same results consistently.^{1,2}

This communication aims at describing the method of applying semi-occlusive dressings to wounds and to highlight a number of important aspects inherent in the "moist wound healing".^{3,4,5}

Material and Method

Our initial study included 200 fingertip injuries. The results will be commented on under "Discussion". With subsequent study more than 600 wounds were treated with "Opsite". These cases include a wide variety of wounds in size, shape and degrees of

sepsis. The aetiological circumstances varied greatly. The approach towards contaminated wounds is different to that of surgically clean wounds.

Semi-permeable dressings are not an alternative for the surgical debridement of wounds which are severely contaminated. The debris and dirt must be removed first before the application of the semi-permeable dressing.

A macroscopically clean wound should be left untouched. However Ringer's lactate or an antiseptic solution could be used to rinse the surface directly after injury because at this stage no biological balance exists yet.

Methods of application:

Although the application of the dressing is simply a matter of sticking the "Opsite" onto the wound (fig 1a-e) the following should be considered:

(a) For a better adherence to the skin it is important:

1. that all greasiness should be removed from the adjoining skin by eg Hibitane and alcohol (fig 1a) One must remember to avoid contact with the wound;
2. the application of TB Co to adjoining skin, assists adhesion;
3. the skin be allowed to dry completely before applying the dressing.

(b) When dealing with uneven or difficult surfaces:

It is recommended to use overlapping strips of dressings to accommodate the curves (fig 1c).

(c) Specific problems:

1. The more extensive a wound the more exudate will form. This can lead to pressure build up or may cause leakage. It is easy to aspirate excessive exudate by a syringe and needle and to seal the puncture with a small patch of dressing (Fig e). For the patient's

The body has an amazing healing ability

Wound Management

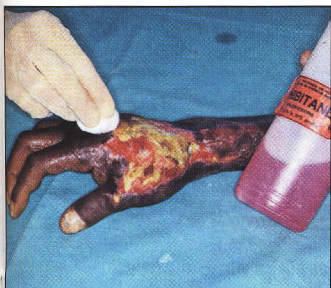


Figure 1a (left): The surrounding skin is cleaned with Hibitane and alcohol. The wound is not touched or cleaned in any way except in the initial stage when obvious dirt and contamination have to be cleaned and the wound debrided. Subsequent wound dressings should not disturb the wound surface.

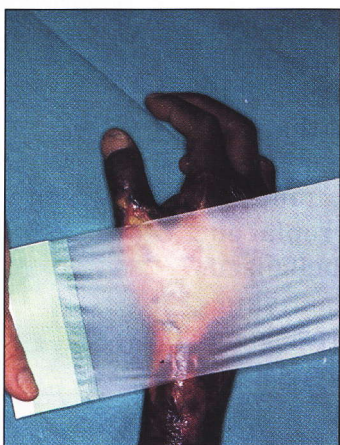


Figure 1b (right): The surface is covered by an "Opsite" sheet.

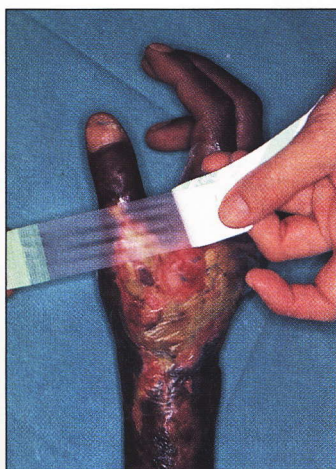


Figure 1c (left): Convex and concave surfaces are covered by overlapping strips of "Opsite".

Figure 1d (right): The "Opsite" is covered by gauze dressing which are kept in place with a crepe bandage. The crepe bandage is, in turn, protected by elastoplast ensuring that the dressing is kept in place when the patient returns to work.

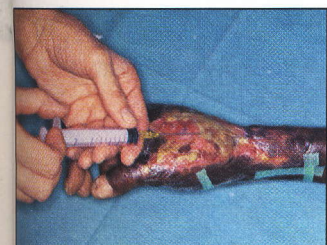
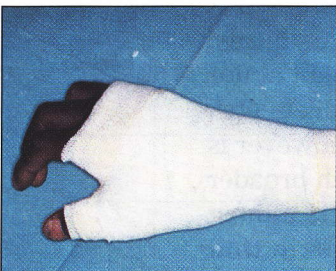

Figure 1e (left): Should any fluid accumulate underneath the "Opsite", this could simply be aspirated and the puncture wound covered by another piece of "Opsite".

comfort and consolation the wound can further be loosely packed with gauze and crepe. This will absorb any leakage and make repulsive wounds more acceptable (fig 1d).

2. Fingertip injuries often develop an offensive smell in which case more frequent repeated dressings should be applied (fig 2).
3. Wounds eg fingertips subjected to excess friction or movement can be protected by elastoplast.

(d) Dressing frequency:

1. Although more extensive or offensive smelling wounds could be changed more frequently (2-3 times weekly) once weekly

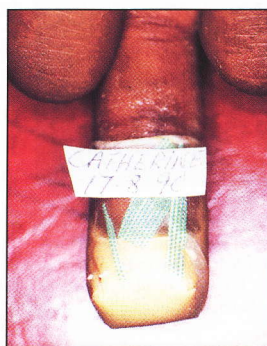

Figure 2: The accumulation of fluid underneath the "Opsite" looks like pus. It often has a foul smell. This is not pus and should not be confused with wound infection. This is a normal response and is beneficial to the healing of the wound. Should the fluid accumulation be copious, simple aspiration through the "Opsite" could be done. Alternatively, the dressing should be removed, the skin only cleaned and another "Opsite" applied.

Colonisation of wounds is an integral part of the healing process.

changes can be considered a good criterion for the "average" wound.

2. Weekly dressings could be done on an outpatient basis, either by the patient himself or at a clinic, such as at work by the nursing sister.
3. For a standard wound on a finger the number of applications varies between six and eight dressings over a period of six to eight weeks.

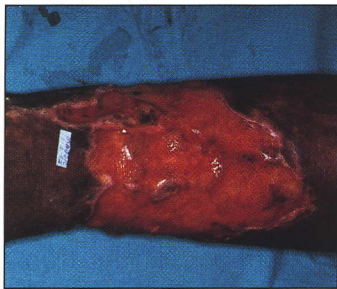
Results

The following figures demonstrate the typical progress of wound healing (figs 3a-c; 4a-b; 5a-c).

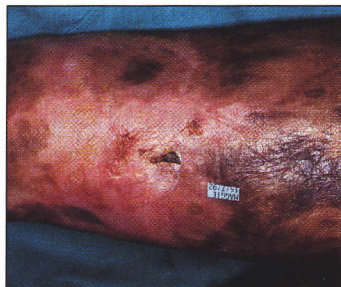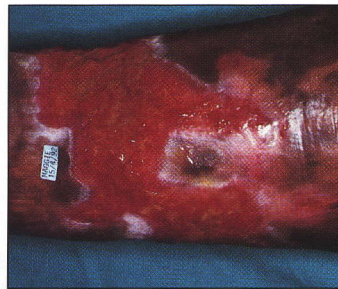
Antibiotics

Antibiotics were only given where

Wound Management



A large burn wound, second degree, involving the forearm. Figure 3a (left) shows the initial wound whereas 3b (right) the progression over time. Figure 3c (below) shows the final result after 14 weeks applying only "Opsite".



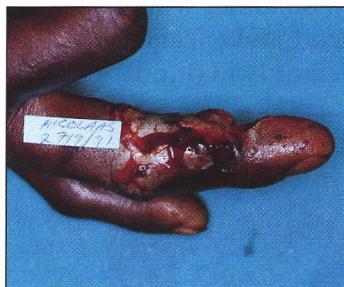
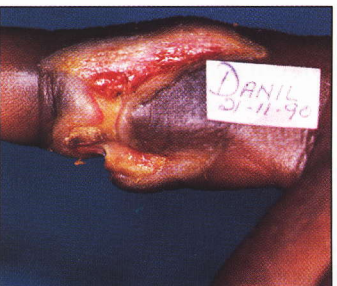patients already had an infection with commencement of the dressings or in special high risk cases such as human bites and diabetes mellitus.

Cultures

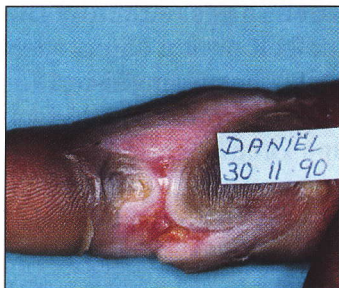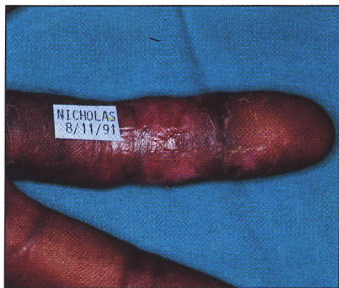Exudate was cultured on a regular basis but in spite of heavy colonisation by different organisms this never lead to infection. These cultures included organisms, such as Pseudomonas, Proteus, alpha-haemolytic Streptococci, beta-haemolytic Streptococci, Staphylococcus aureus, Streptococcus faecalis, Klebsiella, E.coli and even Clostridium species. A typical microbiological profile is demonstrated in table 1 (on page ???). Please note that after epithelialisation has taken place all these organisms disappear spontaneously.

Granulation

Large wounds were allowed to granulate. To speed up the healing process, split thickness skin graft was



Figures 4a and b (above and below) show a crush injury of the index finger which was covered with "Opsite" only. The initial wound and the final result after about six weeks are shown.



Figures 5a, 5b and 5c (left, above and below respectively), represent a chronic infection of the index finger which was planned for amputation. However, "Opsite" dressings were tried first and showed a remarkable response within 10 days. Please note the reduction of the swelling in figure 5b and the final result only 16 days later.

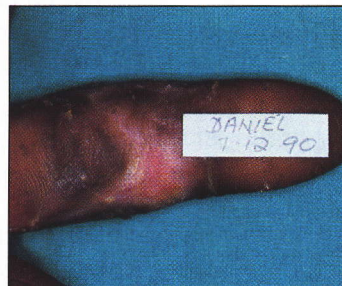used. In all other instances spontaneous epithelialisation has taken place. It should be noted that important soft tissue loss, such as finger pulp is spontaneously replaced (fig 6a-c). Epithelialised with near normal skin, often with fingerprints on is the usual finding (fig 7a-b and 8a-d).

Auto-debridement

It should also be noted that wounds containing dead tissue, need not be debrided as a rule. The body has an ability to auto-debride if left alone. This ability is not well-known and should certainly not be underestimated.

Discussion

Semi-permeable dressings are being used for first and second degree burns, abrasions, split skin donor sites, decubitus ulcers etc⁶. Our contention however is that it has a much broader indication. It acts almost as an artificial skin that



Semi-permeable dressings almost act as an artificial skin.

Semi-occlusive dressing enhances an environment optimal for healing.

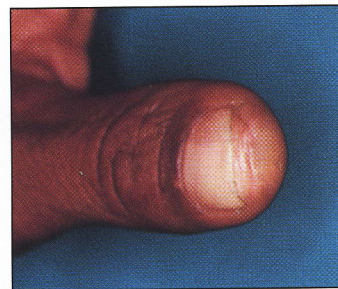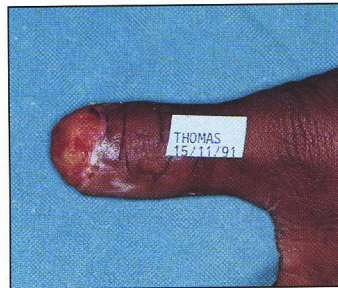
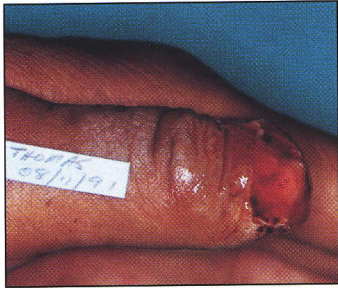Wound Management

Table 1: Organisms cultured in a septic wound during the healing process

No	Date	Pseudomonas Species	Proteus mirabilis	A-Haemolytic Streptococcus	B-Haemolytic Streptococcus	Staphylococcus aureus	Diverse
1	26/2	-	-	-	✓	-	-
2	4/3	-	-	-	✓	-	-
3	11/3	✓	-	-	✓	✓	Peptostreptococcus, Pasteurella
4	18/3	-	-	-	✓	-	-
5	25/3	✓	-	-	✓	-	-
6	1/4	✓	✓	-	✓	-	Clostridium
7	9/4	-	✓	-	✓	-	Pasteurella
8	15/4	-	✓	✓	✓	-	-
9	23/4	-	✓	-	✓	-	-
10	29/4	-	✓	-	✓	-	-
11	20/5	-	✓	✓	-	-	-
12	3/6	-	✓	-	✓	-	Peptostreptococcus
13	10/6	-	✓	-	✓	-	-
14	17/6	-	✓	-	✓	-	-
15	24/6	-	✓	✓	✓	-	-
16	8/7	-	✓	-	✓	-	-
17	16/7	-	✓	✓	✓	-	-
18	22/7	-	✓	-	✓	-	-
19	29/7	-	✓	-	✓	-	-
20	5/8	-	✓	-	✓	-	-
21	12/8	-	✓	✓	-	-	Acinetobacter Corynebacterium bovis
22	19/8	Wound healed no growth					

Note: The various species and the “automatic” disappearance when epithelialisation has taken place

Wound Management

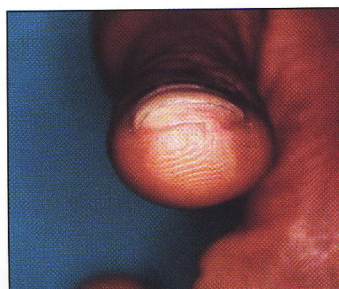
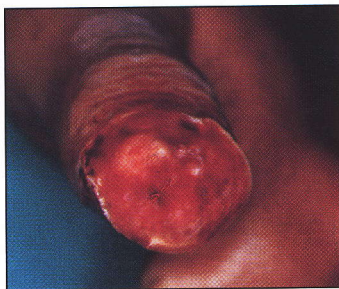
Figures 6a-c: These series of slides represent a traumatic amputation of the thumb involving an invulsion of the nail. The progression is clearly seen with the final result of the thumb. Please note the recovery of a near normal nail, pulp and skin including a "fingerprint"

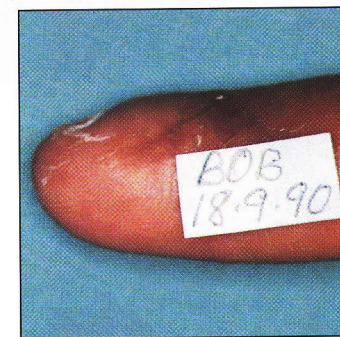
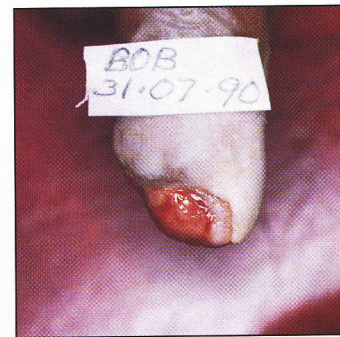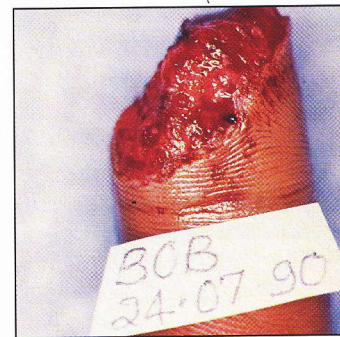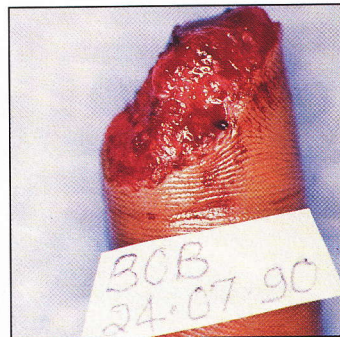occludes the wound to such an extent, that it gives the body a better chance to "get a grip" on the wound. This allows auto-debridement and more effective healing.

With results obtained from more than 800 cases done (all with "Opsite") we have documented the following observations:

Figures 7a and b show the traumatic amputation of the thumb tip involving the nail bed and the remarkable regenerative power of the pulp and fingerprints.



1. The benefits of "moist wound healing" are numerous and outweigh the few disadvantages.
2. An optimal healing environment is created by the semi-occlusive dressing, preventing further contamination.



Figures 8a to d (top to bottom respectively) show a chronic wound of a traumatic amputation which was booked for a surgical revision amputation. However, again "Opsite" dressings were used. The fingertip shape and normal regeneration is clearly seen.

Dressing a wound with gauze disturbs the equilibrium which is necessary for natural healing.

The benefits of "moist wound healing" are numerous.

3. Moist wound healing allows autolytic debridement to take place. This process could be enhanced using wound gels. Our experience however, is that the dressing on its own works very adequately.

Wound Management

4. The moist and stable milieu sustained by the semi-occlusive dressing protects certain important inflammatory cells such as macrophages which form a defence line preventing normal contamination from becoming infection.
 5. Constant disturbance of the wound surface (by frequent dressings) damages delicate newly formed epithelium. "Opsite" does not disrupt this delicate wound surface as is seen with eg gauze dressings.
 6. The transparent plastic allows visualisation of the wound to some extent and excessive exudate can easily be seen and aspirated if need be.
 7. Since these dressings act almost as an artificial skin, it is comfortable, reduces pain and allows patients to return to work virtually the "following day". Fingertips are usually not sensitive and valuable time from work is not lost.
 8. Fingertips regain near normal sensibility and fingerprints even reform to a large extent.
 9. The isolating effect of the dressing often causes a dramatic reduction of swelling of the involved area, the reason being the "protected" environment preventing re-infection whilst allowing free draining of the wound.
 10. The dressings are labour and cost effective.
3. During the warm summer season, and especially in children, hyper granulation may be seen. This problem is solved by using silver nitrate caustic pencils or simply to dry smaller wounds for a day or two. On large surfaces rubbing the surface and applying a split skin graft solves the problem immediately.
 4. Contact dermatitis has been seen with some semi-occlusive dressings. This may probably be due to the allergic reaction to the adhesive glue. This has not been seen with "Opsite".

Some disadvantages of the semi-occlusive dressing are the following:

1. In thin sensitive skin of the elderly and in children, skin maceration may take place if one does not give careful attention to the surrounding skin.
2. The exudate which collects underneath the film dressing resembles pus. This may also have a very foul smell. This should not be confused with frank pus. A bad smell indicates a leaking dressing and is an indication for a dressing change.

Wound colonisation is a normal occurrence and part of normal wound healing. Once the organisms spread into the surrounding tissues the term "wound infection" is used. Wound infection could be diagnosed clinically and by culture from a tissue biopsy. All wounds yield organisms of various kinds and quantity which makes culture and sensitivity tests by swabs of wounds senseless. Once wound infection has taken place (this happens very seldom after wound stabilisation) an appropriate antibiotic should of course be given. The clinical symptoms and signs of an infective process would clearly lead to the diagnosis. It is important to understand that organisms in a wound are a necessity since they have a chemotactic influence on the inflammatory cells such as macrophages and other leukocytes. These organisms do not interfere with the normal healing process at all. Furthermore, they will disappear once the epithelialisation has taken place.

Conclusion

The use of semi-occlusive dressings is a well established method of dealing with all types of wounds. These wounds include macroscopically clean wounds, septic wounds, wounds with slough, wounds in diabetic and leprosy patients, burn wounds, etc.

Management of contaminated wounds is different to surgically clean wounds.

Wound Management

They (especially "Opsite") allow for an optimal healing environment and therefore promote auto debridement, enhance the normal inflammatory reaction by the body, protect epithelialisation and promote a near normal skin cover. It prevents the wound from drying, is comfortable when applied and therefore allows the patient to go back to work, is a simple method to apply, can be taught to the patient and is extremely cost effective.

References

1. Mennen U, Wiese AMJ. Fingertip Injuries Management with Semi-occlusive Dressing. *The Journal of Hand Surgery* 1993;Vol 18B:4:416-22.
2. Mennen U, Wiese AMJ. Semi-Occlusive

Dressing in the Management of Hand Wounds. *SA Bone & Joint Surgery* 1994;Vol IV:4:10-14.

3. Hutchinson JJ. Prevalence of wound infection under occlusive dressings: A collective surgery of reported research. *Wounds: A Compendium of Clinical Research and Practice* 1989;1:2:123-33.
4. Madden MR, Nolan E, Finkelstein JL, Yurt RW, Smeland J, Goodwin CW, Hefton J and Staiano-Coko L. Comparison of an occlusive and a semi-occlusive dressing and the effect of the wound exudate upon keratinocyte proliferation. *Journal of Trauma* 1989;29:7:924-31.
5. May SR. *Physiological Activity from an Occlusive Wound Dressing. Wound Healing Symposium.* Oxford. The Medical Publishing Foundation, 1983:35-51.
6. Eaglstein WH. The Effect of Occlusive Dressings on Collagen Synthesis and Re-epithelialisation in Superficial Wounds. In: Ryan TJ Ed. *Environment for Healing: The Role of Occlusion.* London, The Royal Society of Medicine, 1985;88:31-8.



Medical Sex Journal Subscription

Please complete this form and return immediately

1. I would like to receive the Medical Sex Journal in 1995
2. Please remove my name from the Medical Sex Journal mailing list
3. Comment/Kommentaar _____

Please make cheque payable to:
SA Family Practice, (Medical Sex Journal), P O Box 3172, Cramerville 2060

Please print/Drukletters asseblief

Title/Titel: _____

Address/Adres: _____

Postal Code/Poskode: _____ Telephone/Telefoon: _____

Field of Practice/Praktiseergebied: _____

Subscription/Inskrywing R60,00

Free to Academy Members