

Summary

Objective: To analyse the findings of upper gastro-intestinal endoscopic examinations performed by a family physician in a community hospital and to investigate the implications thereof.

Study Period: Two years

Setting: Mamelodi Community Hospital to the east of Pretoria.

Method and patients: Patients 16 years and older who presented with upper gastro-intestinal problems and in whom endoscopy was indicated, were examined.

Results: 185 Patients (61,6% male) were examined and the following pathology found: oesophagitis (38,4%), oesophageal carcinoma (1,6%), hiatus hernia (13%), gastritis (25,4%), gastric ulcer (12,5%), intra pyloric ulcer (4,3%), duodenal ero-

sion (15,4%) and duodenal ulcer (16,2%). Nocturnal epigastric pain, pain with meals, weight loss, dyspepsia, heartburn and vomiting were the most common presenting symptoms.

Conclusion: Upper gastro-intestinal endoscopy is a valuable diagnostic procedure that could be performed by a family physician in a community hospital. It results in the correct diagnosis in patients presenting with upper gastro-intestinal symptoms and leads to cost-effective management.

Recommendation: Family physicians should be trained to perform upper gastro-intestinal endoscopy to enable them to manage patients with upper gastro-intestinal problems effectively.

**Dr E Moore, MBChB
MPraxMed (Pret), Family
Physician**

**Prof HP Meyer, MBChB,
MPraxMed (Pret) LKAp
(SA), Professor and
Clinical Head, Department
of Family Medicine
Faculty of Medicine
University of Pretoria**

Prof. RJE Erasmus

Dr R Kirkby

**Dept of Family Medicine
Dept of Medicine
P.O. Box 667
PRETORIA
0001**

GASTROSCOPY

Endoscopy of the upper gastro-intestinal tract performed by a family physician in a community hospital

Symptoms of abnormalities of the upper gastro-intestinal tract are generally vague and not diagnostic, which results in the fact that clinical examination of this part of the body is very rarely helpful in the determination of the diagnosis¹.

Patients with significant symptoms and/or clinical signs often have minimal pathology. The opposite is also true. Meyer¹, in a study conducted in private practice in Ermelo, found that 90% of the patients that were examined endoscopically demonstrated epigastric tenderness on clinical examination, while only 3% were anaemic.

Gastritis was the most common finding (25%), followed by hiatus hernia (24%) with reflux oesophagitis in approximately a third of these patients, duodenitis (15%), chronic duodenal ulcer (12%), acute duodenal erosions (11%), chronic stomach ulceration (9%) and narrowing of the pyloric canal (4,5%).

Various studies have been published concerning the cost effectiveness of endoscopic examination². As a consequence of limited funds, an attempt was made to implement a points system whereby a decision could be made as to whether or not upper intestinal endoscopy (gastroscopy) was indicated.

The following factors were considered: age, gender, vomiting, smoking, history of previous ulceration and hiatus hernia. The role of *Helicobacter pylori* was also discussed.

Advantages concerning the request for endoscopic services by family physicians^{3,4} revealed that family physicians generally do not request unnecessary examinations.

Luckers *et al*⁵ asked the question whether or not the request for upper intestinal gastroscopy by family physicians is sensible. In their study, they examined the results of 144 patients' endoscopic examinations. In 52% of cases, abnormalities were found which included: duodenal ulceration (44%), reflux oesophagitis (17%), gastric ulceration (12%), gastritis (11%), bile reflux following stomach surgery (7%), gastric carcinoma (49%) and other pathology (5%).

Results and implications of a two-year study

Following endoscopy, 61 of the 71 patients (86%) could be successfully managed by the family physician. The authors came to the conclusion that "de mogelijkheid rechtstreeks gastroduodenoskopia aan te vragen, lijkt een waardevolle uitbreiding van het diagnostische pakket van de huisarts" (the possibility of direct access to request for gastro-duodenoscopy appears to be a valuable extension of the diagnostic armamentarium of the family physician).

The purpose of this study was to evaluate the results and implications of gastro-intestinal investigations performed by family physicians at a community hospital.

Methods and patients

This was a prospective, descriptive study. Upper gastro-intestinal endoscopy was performed over a two year period (January

**Family Medicine
is similar in some
aspects to other
branches of medicine
but unique in
many others.**

**We aim to
promote original
South African family
medicine research
and are committed
to supporting and
encouraging
researchers new
to the field.**

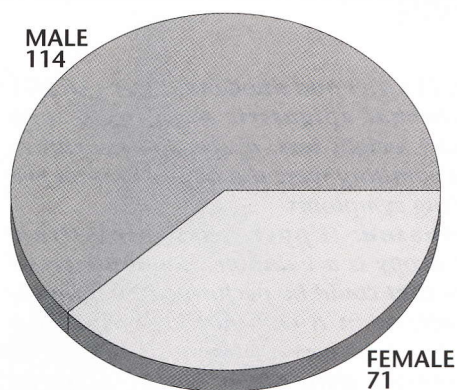


Fig 1. Gender distribution of the patients (n=185)

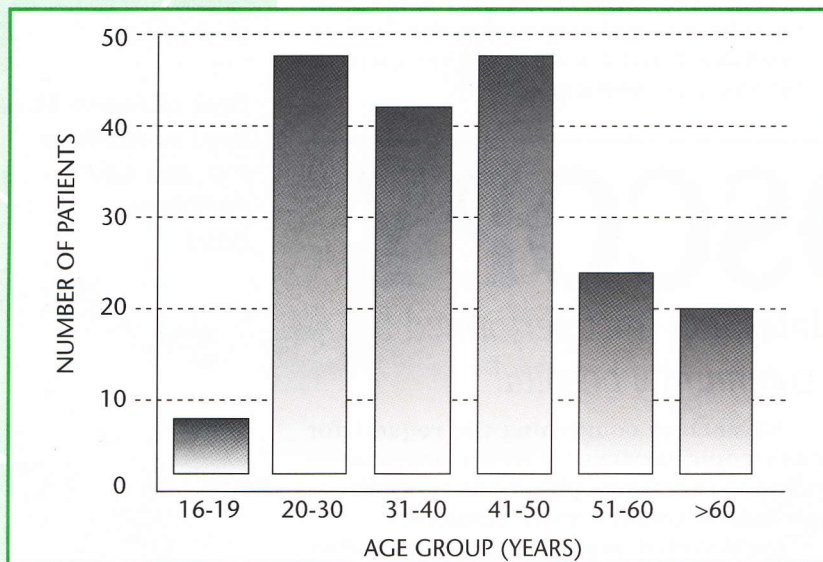


Fig 2. Number of patients per age group (n=185)

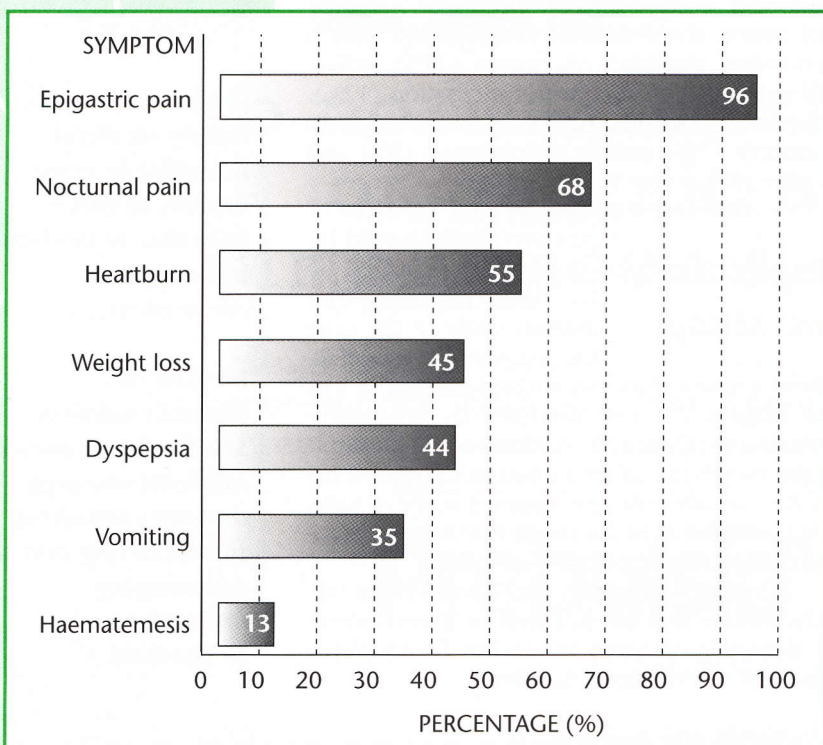


Fig 3. Frequency of symptoms (n=185)

1992–December 1993) by a family physician (EM). The investigations were performed at the Mamelodi Hospital in the east of Pretoria. This hospital is part of the Department of Family Medicine of the University of Pretoria. The family physician was trained by an experienced endoscopist (HM) by performing 50 examinations with a teaching endoscope before working independently.

The following were the inclusion criteria:

Patients 16 years and older with upper abdominal dyspeptic complaints of more than two weeks duration that did not resolve on treatment with an antacid or sucralfate were referred for endoscopy.

Patients who had undergone previous endoscopic evaluation or gastric or duodenal surgery for peptic ulcer disease.

Exclusion criteria

Patients younger than 16 years old, acute gastro-intestinal bleeding and where the indication for gastro-intestinal endoscopy was not for upper abdominal complaints e.g. removal of a foreign body.

The following information was recorded on each patient:

Age, gender, symptoms and clinical signs, cigarette, alcohol and medication or analgesics usage, results of investigations and management.

The investigations were performed with a Pentax FG-27X Gastroscope fitted with a Pentax LH-150 PII light source. The procedure was performed on a day patient basis in an equipped theatre.

The patient fasted overnight from 22h00. Intravenous sedation was administered – Midazolam (Dormicum Roche) 2,5-5,0mg as well as Hyoscine-N-butyl bromide (Buscopan Boehringer Ingelheim E501) 20mg – to facilitate the investigation. Lignocaine spray was used to anaesthetise the throat locally.

All patients had biopsies of the gastric antrum and corpus performed for histology and evidence of *Helicobacter pylori*. Biopsies were also performed of gastric ulcers and any other suspicious looking area. The results of the *Helicobacter pylori* investigations are not discussed further in this study.

Results

- 185 upper gastro-intestinal investigations were performed during this study.
 - 114 men (61,6%) and 71 women (38,4%) were investigated. (See Fig. 1)
- The age distribution is demonstrated in Fig. 2 and the frequency of symptoms in Fig. 3.
- Only seven patients (3,8%) had had previous surgical procedures for gastric or duodenal ulceration. 36 (19,5%) of the patients had a gastroscopic investigation.
 - 82 patients (44%) indicated that they smoked, whereas 68 (36,8%) reported regular alcohol usage. 63 (34,1%) had previously used analgesics whereas 15 (8,1%) reported daily analgesic use.

- A normal oesophagus was seen in 111 patients (60%), oesophagitis in 71 (38,4%) and carcinoma of the oesophagus in 3 patients (1,6%).

The severity of oesophagitis is recorded in Table I.

- With regards to hiatus hernia, a sliding hernia was found in 24 (13%) of the patients (18 men and 6 women). No rolling hernias were found.

The findings in the stomach are depicted in Fig. 4.

- A normal pylorus was found in 131 patients (70,8%). Eight (3,4%) had an intra pyloric ulcer and 46 (24,9%) demonstrated spasm of the pylorus.

The findings in the duodenum are depicted in Fig. 5. The symptoms and clinical signs of different groupings of pathology are depicted in Table II.

Discussion

Nocturnal abdominal pain, abdominal pain with meals, weight loss, dyspepsia, heartburn and vomiting were the commonest symptoms of patients in this study.

Haematemesis and malaena occurred in approximately one tenth of the patients. Few patients had undergone previous surgery, whereas nearly one out of every five patients had had a previous gastroscopy.

Pathology of the upper gastro-intestinal tract was identified in a significant number of patients during this study. (See Fig. 6.) Oesophagitis was the most common finding, followed by gastritis, duodenal ulcers and erosions.

It appears that gender is not a significant factor in the pathology of the upper gastro-intestinal tract except perhaps in men where erosive gastritis and intra pyloric ulceration occurred more commonly. This is possibly due to the high alcohol and cigarette intake. Gastric ulceration showed an increase in prevalence with increasing age (10,1% in the age group 30-50 years, 16,7% in the 50-61-year-old group and 20% in the group of 60 years.) In the peptic ulceration group there were more smokers (66,7% versus 44%).

Conclusions and recommendations

The performance of upper gastro-intestinal endoscopy falls within the spectrum of skills of a family physician provided that satisfactory instruction is obtained and that the indications for the procedure are satisfactory.

According to Rodney⁵ there are six dimensions to gastro-intestinal endoscopic skill. The first is the mechanical skill to handle the equipment, the second is the ability to ascertain and document the diagnostic information, the third is to use the diagnostic information effectively, the fourth is a commitment to examine the results of the information continuously, fifth is the application of new information as the physician becomes more adept at using the equipment and, final-

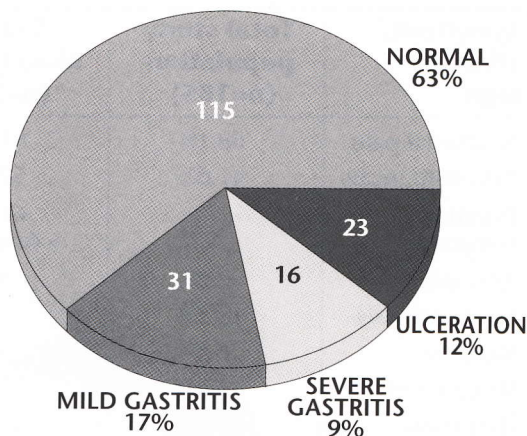


Fig 4. Endoscopic findings in the stomach (n=185)

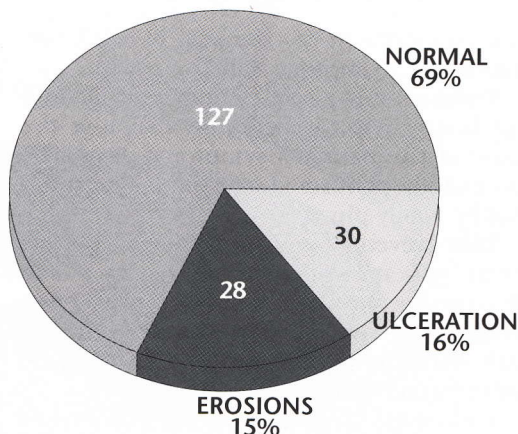


Fig 5. Endoscopic findings in the duodenum (n=185)

Grade	Description	Number (%)
I	Erythema of distal oesophagus	38 (20.5)
II	Longitudinal red lesions in distal oesophagus	27 (14.6)
III	Confluent ulceration in distal oesophagus without stenosis	5 (2.7)
IV	Stenosis in distal oesophagus	1 (0.5%)

Table I. Grading and appearance of oesophagitis (n=71)

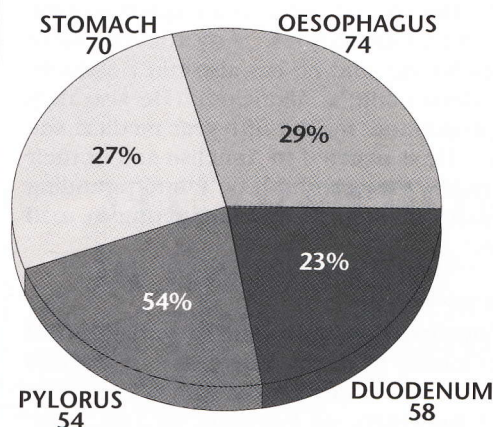


Fig 6. Pathology per anatomical structure

The investigations were performed with a Pentax FG-27X Gastroscope fitted with a Pentax LH-150 PII light source. The procedure was performed on a day patient basis in an equipped theatre.

Oesophagitis was the most common finding, followed by gastritis, duodenal ulcers and erosions.

The performance of upper gastro-intestinal endoscopy falls within the spectrum of skills of a family physician provided that satisfactory instruction is obtained and that the indications for the procedure are satisfactory.

Endoscopy is a safe examination method which can help to accurately diagnose the cause of the patient's symptoms.

Symptom/ clinical sign	Total study population (n=185)	Gastric ulcer group (n=23)	Pyloric ulcer group (n=8)	Duodenal ulcer group (n=30)
Nocturnal pain	68.1%	81%	75%	93.3%
Pain with meals	41.6%	52.4%	50%	46.7%
Duration of symptoms		61% > 6 months	50% > 6 months	66% > 6 months
Anaemia	2.2%	4.8%	12.5%	6.7%
Haematemesis	13.5%	9.5%	Geen	13.3%
Melaena	6.5%	4.8%	12.5%	13.3%
Weight loss	44.3%	57.1%	62.5%	50%
Dyspepsia	45%	57%	62.5%	46.7%
Heartburn	55%	62%	87.5%	40%
Vomiting	34.6%	47.6%	50%	60%

Table II. Prevalence of symptoms and clinical signs in each pathology group.

ly, a commitment to take part in a training programme to improve skills.

Endoscopy is a safe examination method which can help to accurately diagnose the cause of the patient's symptoms. It can be successfully performed in a community hospital by family physicians.

This prevents unnecessary financial costs for the patients such as transport, admission to larger hospitals and more expensive costs incurred by specialists. It also aids in the early detection of malignant lesions of the gastro-intestinal tract.

Endoscopy should be an integral part of the professional training of family physicians, and co-ordinators of post-graduate training programmes for family physicians should provide the necessary training opportunities. ●

References

1. Meyer HP. *Gastroskopiese ondersoek deur die algemene praktisyn. Algemene oorsig en evaluasie van 'n reeks van 200 pasiente.* Ongepubliseerde MPraxMed skripsie, Universiteit van Pretoria, 1982.
2. Mann J, Holdstock G, Harman M, Machin D, Loehry CA. *Scoring system to improve cost-effectiveness of open access endoscopy.* BMJ 1983;287:937-939.
3. Luckers AEG, Thijs JC, Westerveld BD, Festen HPM, Meuwissen SGM. *Is endoscopie van de proximale tractus digestivus op versoek van de huisarts zinvol?* Ned Tijdschr Geneesk 1985;129 (3): 117-119.
4. Hungin AS. *Use of open-access gastroscopy service by a general practice: Findings and subsequent specialist referral rate.* JR Coll Gen Pract 1987;170:171.
5. Rodney WM. *Gastroenterology.* In Rakeil RE (auth). *Textbook of Family Practice.* 5th Ed. Philadelphia: WB Saunders Company, 1995: 1225.

About the authors

Dr Erwin Moore

Dr Erwin Moore grew up in Nigel, where he matriculated. He achieved his MBChB at Pretoria University in 1989 and completed his Internship at Tembisa Hospital. He has worked at Middelburg Hospital and Mamelodi Hospital, where he is currently a consultant in the Department of Family Medicine. He was awarded his MPraxMed in 1994. His special interests are gastroenterology and gastroscopies. Any theatre work makes his day and he has also run a successful asthma clinic at Mamelodi. He also runs the programme for the fifth-year medical students. He is married to Annelise and in their spare time they can both be found pounding the roads of Pretoria and competing in road races.

Prof HP Meyer

Prof Helgard Meyer qualified with MBChB (cum laude) from the University of Pretoria in 1976. He received the MPraxMed from the University of Pretoria in 1982 and attained the MFGP (SA) in 1983, being awarded the Claude Leon Harris Medal.

Helgard practised as a family practitioner


in Ermelo from 1981 to 1989 and was then appointed as professor and clinical head, Department of Family Medicine, University of Pretoria, in 1990. His main interest lies in the chronic fatigue/fibromyalgia group of disorders and he has presented more than 80 papers, posters and lectures at local and international congresses, symposia and seminars. He is married to Katinka and they have three children.

Prof RJE Erasmus


See page 4

Dr R Kirkby

Russell Kirkby spent nearly 17 years in private practice before joining academic Family Medicine at Pretoria University. He is Principal Family Physician at Mamelodi Community Hospital as well as a senior lecturer in the department. He currently attends many meetings, is a major paper shuffler and occasional clinician. He hopes to remain true to the commitment to remember the real world of medicine and remind Academia to consider the world outside the Ivory Towers in their deliberations. Russell is married to Robyn, a radiographer, and they have four daughters.



Dr Erwin Moore



Prof HP Meyer