

# Allergic conditions of the eye

Smit D, MBChB, DipOphth, FCOphth, MMed(Ophth)

Department of Ophthalmology, Faculty of Health Sciences, Stellenbosch University, Tygerberg Hospital

**Keywords:** allergic contact dermatitis, atopic dermatitis, allergic conjunctivitis, vernal keratoconjunctivitis, atopic keratoconjunctivitis, contact lens-induced conjunctivitis

© Medpharm

Reprinted from S Afr Pharm J 2010;77(9);22-27

## Introduction

Patients suffering from allergic conditions affecting the eye present to primary healthcare providers on a daily basis. It is important to note that many of these conditions are transient in nature and do not cause any permanent damage to the eye, whereas other, more chronic forms are vision-threatening and may lead to irreversible ocular damage if misdiagnosed and not treated appropriately.

In this article, the different guises of ocular allergy will be described, along with helpful hints that will aid in reaching the correct diagnosis and management of each. Conditions predominantly affecting the eyelids will be discussed first, followed by those primarily affecting the ocular surface and finally those associated with contact lens wear.

## Allergic conditions affecting the eyelids

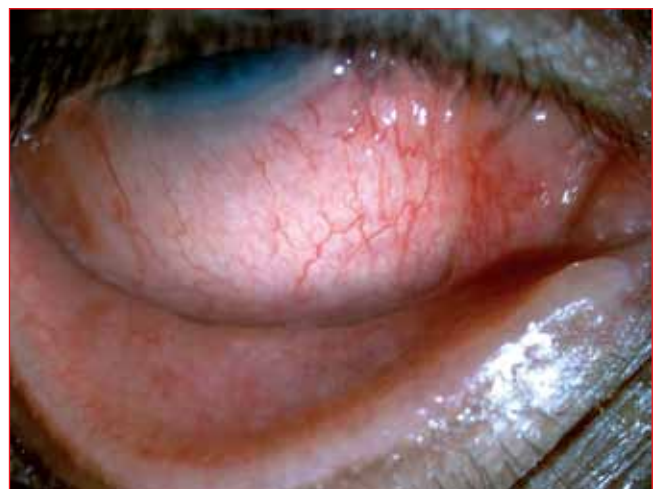### Allergic contact dermatitis

These allergic reactions may be triggered by topical application of medications and cosmetics, or by substances originating from the environment. The reactions may manifest acutely as a form of anaphylaxis, or may have a delayed onset where symptoms and signs manifest 24-72 hours after exposure to the allergen. The delayed response requires prior sensitisation to the substance in question and patients are often able to recall previous exposure to this agent. Patients with acute allergy only rarely show signs of systemic anaphylaxis, such as laboured or rapid breathing and increased heart rate. Such cases require urgent referral to a medical emergency unit.

### Clinical picture

The characteristics of acute allergic reaction are as follows:

- Develops within minutes after exposure to the allergen.
- Itching, erythema (redness) and swelling of the eyelids.
- Erythema and chemosis (swelling) of the conjunctiva (Figure 1).



**Figure 1:** Erythema and chemosis of the conjunctiva in a patient suffering from acute contact dermatitis of the eyelids

A delayed allergic reaction is characterised by the following:

- Develops 24 – 72 hours after re-exposure to the offending agent.
- Erythema, leathery thickening and scaling of the eyelids in the early stages.
- Hyperpigmentation and scarring of the eyelid skin later on.
- Conjunctival erythema and mucoid discharge often present.

### Management

Identification and discontinuation of the causative agent is the mainstay of treatment and appropriate advice should therefore be given if the history clearly identifies the cause. However, if the cause is uncertain, the patient should be referred to an allergist.

In most acute cases, antigen withdrawal and supportive treatment with cold compresses and artificial tears will suffice. Adjunctive treatment with topical and/or oral antihistamines may be required in cases not responding to simpler measures.

Most mild delayed reactions will also respond to antigen withdrawal and simple supportive measures as outlined above. More severe cases may require topical application of corticosteroids to the eyelids and eye.

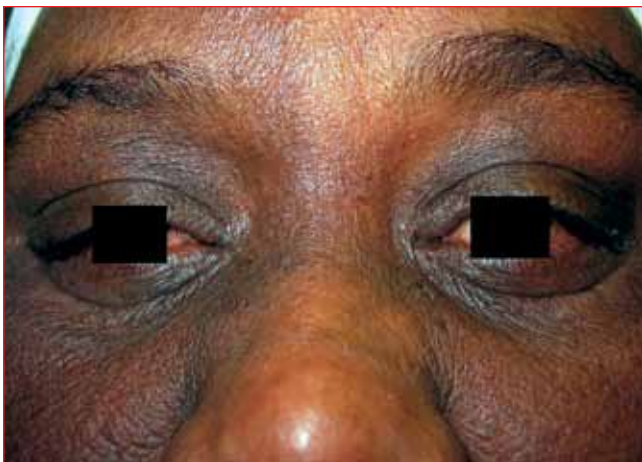### Atopic dermatitis

Atopic dermatitis usually manifests in infancy or early childhood in individuals who have a personal or family history of other atopic conditions such as asthma, hay fever or allergic rhinitis. The disease is characterised by chronic, pruritic skin lesions that typically affect the face and the extensor surfaces in infants and young children, while involvement of the joint flexures is more typical in adolescents and adults.

#### Clinical picture

The appearance of the skin lesions varies with age:

- Infants: Pruritic, erythematous rash on the face and extensor surfaces.
- Children: Similar to above, but with secondary lichenification (thickening of the skin) due to constant scratching.
- Adults: Red, scaly, pruritic patches with dry, thickened and wrinkled skin (Figure 2).



**Figure 2:** Thickened, wrinkled skin around the eyes of an adult with atopic dermatitis

#### Management

Reduction of exposure to environmental allergens is once again a key aspect in managing these patients. The patient should be advised to consult an allergist to identify the allergen(s) in question and provide expert counselling regarding the overall management of the condition.

Oral antihistamines may be given to alleviate itching, while emollient creams can be used to soften the skin and improve hydration.

Topical corticosteroid creams or ointments are often needed to control acute lesions, but it is important to not that local absorption from the eyelids may lead to raised intraocular pressure in steroid-sensitive patients.

### Allergic conditions affecting the ocular surface

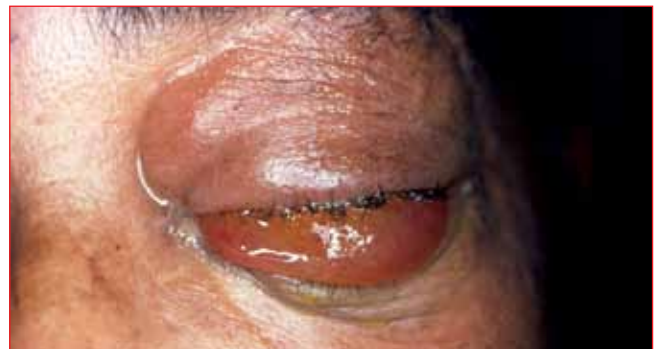#### Seasonal and perennial allergic conjunctivitis

These conditions typically occur in response to airborne allergens that come into contact with mast cells in the conjunctiva. The mast cells subsequently release histamine and various other chemical mediators that cause dilation of blood vessels and swelling of the conjunctiva. If an individual was previously sensitised to the specific allergen, it may take only a few minutes for the clinical picture to develop. Patients with allergic conjunctivitis often suffer from other forms of atopy, such as asthma or allergic rhinitis.

#### Clinical picture

Typical symptoms and signs include:

- Characteristic sudden onset of intense ocular itching.
- Swelling of the eyelids and conjunctiva (Figure 3).
- Conjunctival redness/hyperaemia.
- Mucoid discharge from the eyes and nose.



**Figure 3:** Swollen eyelids and conjunctiva in acute allergic conjunctivitis

#### Management

Prevention forms an important part of the management of this condition by avoiding or, at least, reducing exposure to known allergens. However, once the clinical picture is present, the treatment should be based on the severity of the patient's symptoms.

Cold compresses may be all that is required in mild forms of the disease. Ice packs should never be applied directly to the eyelids, but rather be covered by a protective layer, such as a facecloth.

Artificial tears, especially when chilled, provide symptomatic relief in mild cases and also serve to dilute and flush away allergens and inflammatory mediators from the surface of the

eye. Preservative-free preparations, such as carmellose in single dose vials [e.g. OPTIVE® unit dose vials (preservative free), Tears Naturale® Preservative Free, Cellufresh®, or Celluvisc®], may be preferable.

Topical vasoconstrictors, such as oxymetazoline, naphazoline and tetraizoline, are sometimes used alone or in combination with antihistamines such as antazoline (e.g. Spersallerg®) to provide short-term symptomatic relief. However, prolonged use may lead to rebound conjunctival hyperaemia, which often takes a long time to clear and explains why most ophthalmologists prefer not to use these medications.

Topical antihistamines, such as emedastine and levocabastine, are useful for providing quick relief from the symptoms of allergic conjunctivitis. Oral antihistamines, i.e. selective H<sub>1</sub> receptor antagonists, may also alleviate ocular symptoms.

Topical mast-cell stabilisers, such as sodium chromoglycate and lodoxamide, play a predominantly preventative role and are therefore used more frequently in chronic allergic conditions.

Topical medications with both antihistamine and mast-cell stabilising properties, such as epinastine, olopatadine and ketotifen, are popular choices since they quickly relieve symptoms, but also help to prevent recurring episodes of ocular itching.

Other medications, such as topical nonsteroidal anti-inflammatory drugs (NSAIDs) or topical corticosteroids, may be required in specific cases.

### Vernal keratoconjunctivitis

Vernal keratoconjunctivitis (VKC), or spring catarrh, is a bilateral inflammation of the cornea and conjunctiva that often flares up during springtime, although in hotter climates patients experience symptoms throughout the year. It most commonly occurs in young boys, who often have either a personal or family history of atopy. Most patients who suffer from VKC fortunately outgrow the condition during puberty.

#### Clinical picture

Signs and symptoms include:

- Severe, chronic ocular itching.
- Sensitivity to light (photophobia) and inability to open the eyes due to discomfort (blepharospasm).
- Blurred vision.
- Mucoïd discharge.

Signs tend to occur either under the upper eyelid (palpebral form) or around the cornea (limbal form). In the palpebral form, giant papillae may form on the conjunctiva under the upper eyelid (Figure 4). This form is commonly seen

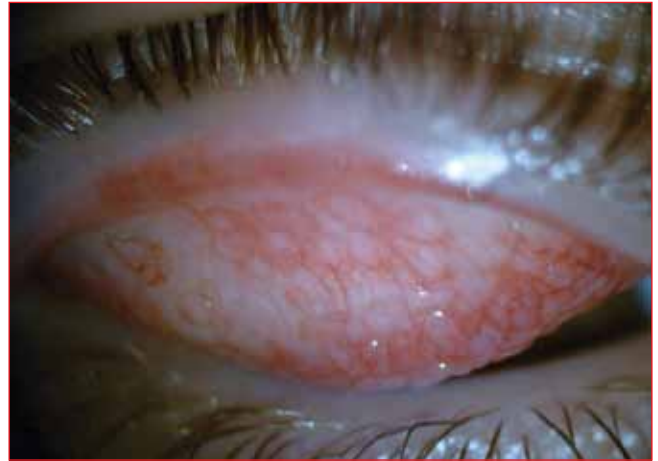

Figure 4: Vernal keratoconjunctivitis (palpebral form)

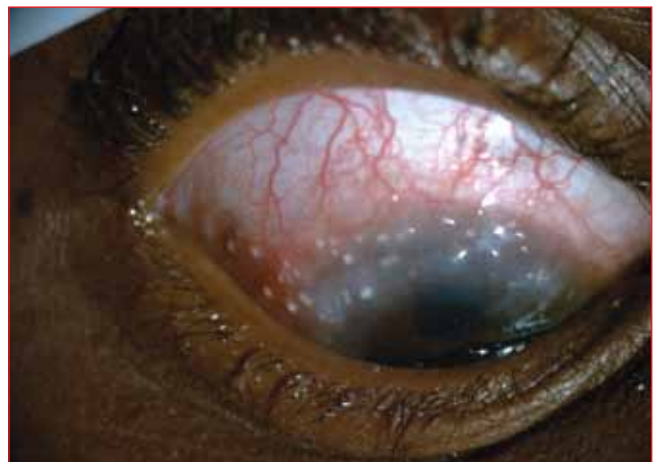

Figure 5: Vernal keratoconjunctivitis (limbal form showing Trantas dots)

in less pigmented individuals living in cooler climates. In the limbal form, a thickened, gelatinous ring may form around the cornea, which often contains whitish dots called Trantas dots (Figure 5). This form frequently occurs in more pigmented patients who live in hotter climates.

#### Management

Treatment should, once again, be based on the severity of the patient's symptoms, as well as the degree of ocular surface disease. An increase in severity usually equates to an increase in the number of different drugs required for adequate disease control. If treatment is inadequate, progressive corneal damage may eventually lead to blindness.

In mild cases, topical antihistamines and artificial tear drops usually provide sufficient control.

In moderate cases, long-term administration of a topical mast-cell stabiliser (lodoxamide) is required in addition to topical antihistamines and lubricants. Oral antihistamines are also useful to ameliorate itching.

Severe cases often need short courses of topical corticosteroids, such as prednisolone acetate or dexa-

methasone phosphate, in addition to the drugs listed above in order to gain control of the disease. These drugs should only be used under specialist supervision, since raised intraocular pressure and even cataracts may result from injudicious long-term use.

Topical preparations of immunomodulatory drugs, such as ciclosporin and tacrolimus, are also used in the most severe cases under strict specialist supervision.

### **Atopic keratoconjunctivitis**

Up to two-thirds of patients with atopic dermatitis develop ocular involvement, atopic keratoconjunctivitis (AKC) occurring most commonly. Like VKC, it is a chronic, bilateral inflammation of the cornea and conjunctiva and the two conditions therefore share some common clinical characteristics on the one hand, but also show significant differences on the other.

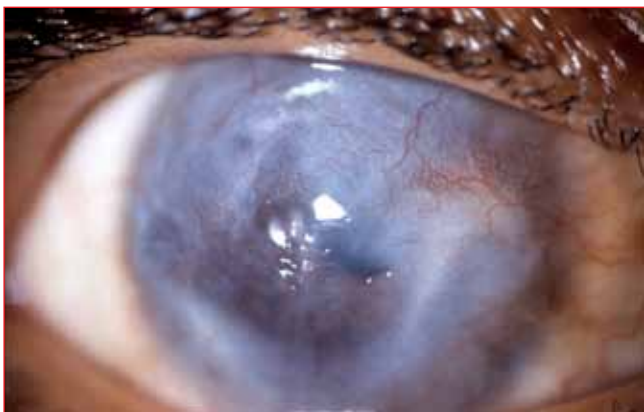
#### *Clinical picture*

Similarities to VKC include:

- Itching as the major symptom.
- Mucoïd discharge, blurred vision and photophobia.

Differences from VKC include:

- No gender or geographic predilection.
- Perennial disease more common with minimal seasonal exacerbation, which are more common in the presence of animals.
- Usually presents from the second decade onwards, i.e. it starts when most VKC patients begin to outgrow their disease.
- Giant papillae are usually not present on the conjunctiva.
- The conjunctiva often shows “milky” swelling.
- Significant scarring and neovascularisation of the cornea may occur, which often leads to blindness if not managed correctly (Figure 6).



**Figure 6:** Scarring and neovascularisation of the cornea in atopic keratoconjunctivitis



### Management

Similarly to atopic dermatitis, management strategies include reduction of exposure to environmental allergens and the use of oral antihistamines. Topical antihistamines, such as levocabastine and emedastine, help to alleviate symptoms and may be required long term.

Topical mast-cell stabilisers, such as sodium chromoglycate and lodoxamide, reduce itching and tearing. Drugs that have an antihistamine effect in addition to mast-cell stabilisation, such as epinastine, olopatadine and ketotifen, are also very useful. These agents may be needed on a chronic basis in patients with perennial symptoms.

Topical immunomodulatory drugs, such as corticosteroids and ciclosporin, are often required in patients who do not respond adequately to more conservative measures. These drugs should only be used under specialist supervision.

### Contact lens-induced conjunctivitis

Contact lens wear may be associated with different types of conjunctivitis. These are either caused by an allergic reaction to contact lens solution (contact lens allergy), or by mechanical rubbing of the contact lens against the conjunctiva combined with long-term exposure to proteins on the surface of the contact lens (giant papillary conjunctivitis).

#### Contact lens allergy

The clinical picture of contact lens allergy is very similar to that of seasonal allergic conjunctivitis (SAC), since it is characterised by ocular itching, erythema, chemosis and tearing. The distinction lies in the history of contact lens wear in these patients, as opposed to one of atopy and seasonal exacerbation in patients suffering from SAC. The condition is self-limiting and resolves once the offending solution is withdrawn.

#### Giant papillary conjunctivitis

##### Clinical picture

Giant papillary conjunctivitis (GPC) closely resembles VKC, but it occurs in contact lens wearers as opposed to atopic patients. Wearers of soft contact lenses are more often affected than those wearing rigid contact lenses.

Symptoms and signs include:

- Varying degrees of itching.
- Foreign body sensation.
- Mucus covering the contact lenses.
- Limited conjunctival injection.
- Giant papillae under the upper eyelid, identical in appearance to those seen in VKC.

### Management

The aim of treatment in GPC is to resolve symptoms and thereby, if possible, enable the patient to continue wearing contact lenses.

Reducing the amount of contact time between the conjunctiva and the contact lens is the most important step in managing this condition.

Changing the disinfection system to hydrogen peroxide and preservative-free solutions instead of heat or preserved chemicals is preferred. Frequent enzymatic cleaning of the lenses, i.e. at least once a week, will help remove the instigating proteins from the lens surface.

Referral to a registered contact lens practitioner to optimise both lens type and fit is often necessary. Daily disposable lenses are preferred for patients with GPC.

Pharmacological intervention is less important in the treatment of GPC when compared to other forms of ocular allergy. Lodoxamide or sodium chromoglycate may be useful in early cases, but often short courses of topical corticosteroids are required to bring symptoms under control.

### Conclusion

Allergic conditions affecting the eyes and eyelids may present in many different ways, and thus it is important that the primary health care provider possesses an adequate understanding of these conditions. Considerable overlap may occur with regard to presenting signs and symptoms, but often the correct diagnosis can be made by simply asking a few pertinent questions regarding matters such as atopic history and contact lens wear.

Many of these conditions will resolve either spontaneously or with conservative intervention, whereas others may be exceptionally difficult to treat and have the potential to cause significant loss of vision. Figure 7 demonstrates a stepwise approach that may be used in the treatment of most forms of ocular allergy, and reiterates that the same process should be followed for all patients. By initially reducing antigen exposure and then judiciously adding different medications depending on the severity of the disease, the vast majority of patients will respond in a satisfactory manner.

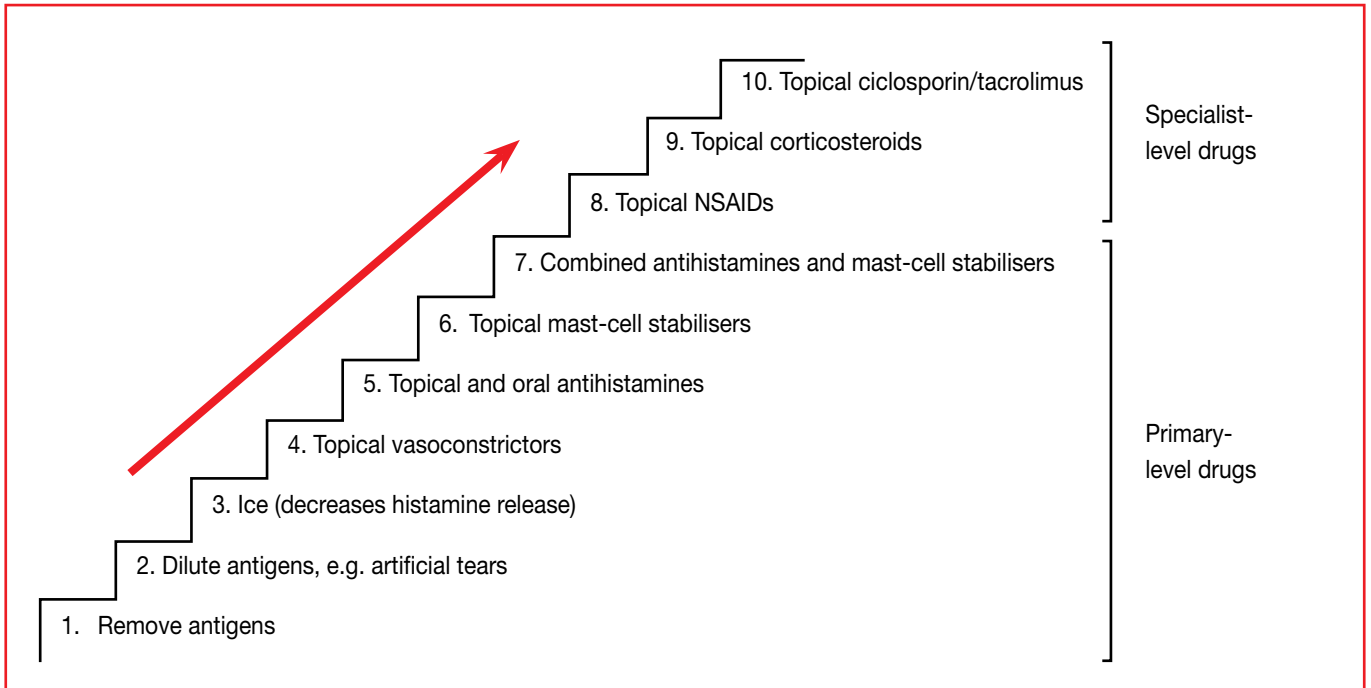


Figure 7: Stepwise approach that may be used in the treatment of most forms of ocular allergy (courtesy of Prof D Meyer)