

Chronic sinusitis in children: a general overview

Friedman RL, MBChB, FCS (SA) ORL

Private Practice, Sandton MediClinic and Netcare Linksfield Clinic

Correspondence to: Raymond Friedman, e-mail: friedmanr@surgeon.co.za

Keywords: chronic sinusitis, rhinosinusitis, children

Peer reviewed. Reprinted with permission from South Afr J Epidemiol Infect 2011;26(1):13-17. © SAJEL. S Afr Fam Pract 2011;53(3):230-239

Introduction

Rhinosinusitis is a significant and increasing health problem, resulting in a large financial burden on society. It is multifactorial in origin. With age, several predisposing factors change and rhinosinusitis manifests differently. Management thereof is evolving and controversial.¹ Usually, rhinitis and sinusitis appear concurrently in most individuals, therefore the correct terminology is "rhinosinusitis".¹ The case definition has been stratified into a technical description that is useful for ear, nose and throat specialists, and a clinical definition that is pertinent for other healthcare professionals.

Technical definition

Rhinosinusitis is defined as inflammation of the nose and paranasal sinuses¹ characterised by two or more symptoms, one of which should be either nasal blockage/obstruction/congestion, or a nasal discharge (anterior/posterior nasal drip). Other symptoms include facial pain or pressure, a reduction in or loss of smell, and either endoscopic signs of polyps and/or mucopurulent discharge, primarily from the middle meatus, oedema/mucosal obstruction, also primarily in the middle meatus, and/or computerised tomography (CT) changes showing mucosal changes within the ostiomeatal complex and/or sinuses.

In order to more accurately clinically define rhinosinusitis, classifications need to be understood. Available evidence and clinical experience have been correlated to better define and understand clinically similar and often related conditions.¹⁻³ The role of allergy in chronic rhinosinusitis in children is mentioned here because of the difficulties in differentiating persistent allergic rhinitis from chronic sinusitis. Allergy is accepted as a cause of chronic rhinosinusitis, but only as one of several factors.^{4,5} In order to differentiate between the two symptomatically very similar clinical entities, the concept of Allergic Rhinitis and its Impact on Asthma (ARIA)² is presented to facilitate allergic rhinitis diagnosis.

Allergic rhinitis

Allergic rhinitis (see Figure 1) is defined as inflammation of the lining of the nose characterised by nasal symptoms, including anterior or posterior rhinorrhoea, sneezing, nasal blockage and/or itching of the nose, and is often associated with ocular symptoms (itchy, red and watery eyes).² Itching, sneezing and profuse rhinorrhoea are classic signs of early allergic rhinitis. However, with time, nasal obstruction predominates.⁶ The allergy must be confirmed by current history, skin prick tests and/or radioallergosorbent testing (RAST), an in vitro test for specific IgE allergy antibodies. According to the ARIA classification, severity and chronicity can be subdivided again.²

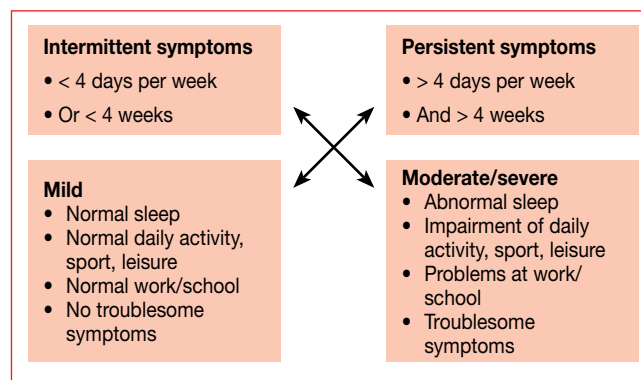


Figure 1: Classification of allergic rhinitis

Allergic rhinitis can therefore present as:

- Intermittent-mild;
- Intermittent-moderate/severe;
- Persistent-mild; or
- Persistent-moderate/severe.

In children with chronic rhinosinusitis and with a suggestive history of allergy (asthma and eczema), and/or physical signs (allergic salute, watery rhinorrhoea, nasal blockage, sneezing and boggy turbinates), an allergic assessment (skin prick and RAST) should be performed.

Clinical definition: rhinosinusitis

The *European position paper on rhinosinusitis and nasal polyps, 2007* (EPOS),¹ recognised the need for different emphasis on definitions used by otorhinolaryngology clinicians, as opposed to those used by other non-otorhinolaryngological practitioners. The non-otorhinolaryngological clinical definitions are used here.¹

*Rhinosinusitis (non-ORL)*¹

Two or more symptoms:

- One of which should be either nasal blockage/obstruction/congestion or nasal discharge (anterior/posterior nasal drip).
- Facial pain or pressure.
- A reduction in, or loss, of smell.

Rhinosinusitis can be further classified:

Acute rhinosinusitis

- Sudden onset.
- Duration must be less than 12 weeks and with symptom-free intervals if the problem is recurrent. Questions on allergic symptoms, i.e. sneezing, watery rhinorrhoea, nasal itching, and itchy, watery eyes, should be included.

Acute viral rhinosinusitis (common cold)

The definition of acute viral rhinosinusitis is a duration of symptoms for less than 10 days.

Incidence is very high. Adults get two to five colds per year and schoolchildren, seven to ten colds per year. Rhinovirus (24%) and influenza virus (11%) are the most common isolated agents. Approximately 0.5-2% are complicated by bacterial infection.¹ All clinicians should be familiar with the cold's natural history so that deviation from the norm can be managed effectively. Clear nasal secretions frequently become purulent without signifying secondary bacterial disease, and coughing is a normal accompaniment.⁷

Acute non-viral rhinosinusitis

The definition of acute non-viral rhinosinusitis is an increase of symptoms after five days, or persistent symptoms lasting longer than 10 days and less than 12 weeks.³ Treatment may be necessary for acute bacterial sinusitis.

*Chronic rhinosinusitis with or without nasal polyps*¹

The definition of chronic rhinosinusitis is two or more symptoms, one of which should be either nasal blockage, obstruction, congestion, or nasal discharge (anterior/posterior nasal drip). Other symptoms include an increase or decrease in facial pain/pressure, and an increase or decrease in reduction of, or loss of, smell. The duration of symptoms should last longer than 12 weeks without complete resolution of symptoms.¹

Severity is divided into mild, moderate and severe, mostly based on the total severity visual analogue scale (VAS) score:

- Mild = VAS 0-3;
- Moderate = VAS > 3-7;
- Severe = VAS > 7-10.

An otorhinolaryngological opinion should be sought with:

- All severe cases;^{1,3}
- Failed adequate, compliant treatment; and
- Extension of disease outside the sinuses.

Special groups of chronic rhinosinusitis that require relevant multi-specialist management include cystic fibrosis, fungal infections and primary ciliary dyskinesia. Another difficult group is chronic rhinosinusitis after sinus surgery. Any mucosal disease without overt polyps should be regarded as chronic rhinosinusitis (without polyps).¹

Chronic rhinosinusitis**Anatomy and pathophysiology in chronic rhinosinusitis**

The paranasal sinuses are a complex series of four paired hollow cavities extending through various small passages into the anterior skull. Maxillary sinuses lie under the cheeks, ethmoid sinuses between the eyes on either side of the nose (complex and "honeycomb" in nature), frontal sinuses above the eyes in the forehead, and sphenoid sinuses at the back of the nose under the base of the skull.

Pseudostratified columnar ciliated epithelium extends from the nose via the ostiomeatal complexes into these sinuses.

An ostiomeatal complex is a functional unit, comprising key elements of the nose and sinus anatomy, including the sinus ostia. Maintenance of ostial patency and the functional mucociliary blanket is paramount in sinus health. Any obstruction within this ostiomeatal complex will lead to stasis, stagnation and inflammation. In the chronic form, once inflammation is established, the role of the ostium seems less of an issue than in acute disease.¹ Mucosal surface contact, in the important transition spaces within the paranasal sinus complex, is the main determinant of disease initiation and progression as described by Messerklinger,⁸ Wigand⁹ and Stammberger.¹⁰

Sinus development appropriate to diagnosis

The maxillary sinuses are the first to develop.¹¹ At birth, they are usually fluid-filled. Growth is initially biphasic (zero to three years, and seven to twelve years). During the later phase, pneumatization spreads more inferiorly as the permanent teeth migrate. The ethmoid sinuses are fluid-filled in a neonate. Anterior cells form first in utero, followed by the posterior cells. The cells reach adult size by age 12. By one year of age, ethmoid sinuses are usually seen on radiographs.

The frontal sinuses develop as an upward extension of the most anterior ethmoid cells. The frontal bone, membranous at birth, begins to ossify around age two. X-rays seldom show it before that time. True growth begins at age five and continues into the late teens.

The sphenoid sinuses are present, but remain undeveloped until age three, and are not seen on X-rays before that. By age seven, pneumatization has reached the sella turcica. By the age of 18, the sinuses have reached full development.

Chronic rhinosinusitis: clinical

Chronic rhinosinusitis is a clinical syndrome, associated with persistent inflammation of the mucosa of the nose and paranasal sinuses. Chronic rhinosinusitis includes the polypoid (CRSwNP) and non-polypoid (CRSSNP) forms. Historically, CRSSNP was considered to result from incompletely treated acute infectious sinusitis. CRSwNP was believed to be a distinct non-infectious disorder of unclear origin, perhaps related to atopy. More recently, the aetiology of chronic rhinosinusitis has been regarded as complex, multifactorial and as a distinct entity. The concept of "chronic mucosal inflammation" has replaced "infection" to describe chronic rhinosinusitis.^{4,5}

Nasal polyps are grape-like structures comprising loose connective tissue, oedema, inflammatory cells, glands and capillaries originating from the nose and sinuses.¹ They are covered mostly with respiratory pseudostratified epithelium with ciliated cells and goblet cells. Eosinophils are the most common cellular element, but neutrophils, mast cells, plasma cells, lymphocytes and monocytes are also present. Interleukin 5 is the predominant cytokine reflecting activation and prolonged survival of eosinophils. It is unknown why this subset of chronic rhinosinusitis sufferers develops nasal polyps. Recurrence after surgery and a relationship (Samter's triad) with asthma and nonsteroidal anti-inflammatory drug (NSAID) sensitivity are particularly interesting features.¹

Prevalence of nasal polyps in the general population is four per cent, rising in asthmatics to seven to fifteen per cent. In NSAID sensitivity, nasal polyps are found in 36-60% of patients. There is doubt that allergy predisposes to nasal polyposis. CRSwNP shows no racial differences, but men are more frequently affected than women. CRSwNP is seldom seen in people younger than 20 years. Cystic fibrosis is the exception.¹

The sinonasal epithelium provides a mechanical and innate immune barrier to many environmental agents. This barrier also plays a key role in regulating the acquired mucosal immune response in the nose. Recent studies suggest that defects in this barrier may foster chronic sinonasal inflammation in response to environmental agents and pathogenic or commensal organisms. The ability to dissect and analyse defects in the inflammatory response

in rhinosinusitis may help identify novel targets for drug development.^{4,5}

Epidemiology of rhinosinusitis specific to children

CT and magnetic resonance imaging (MRI) findings have shown:¹

- The "runny nose child" has more rhinitis and adenoidal issues.
- On average, 45% of children had signs of sinusitis.
- A history of nasal obstruction increased this incidence to 50%.
- With clinical mucosal swelling, this rose to 80%, and to 100% in the presence of purulent secretions.
- After a six to seven months follow-up, up to half had resolved without intervention.
- A decrease in the prevalence of rhinosinusitis in older children is apparent.

Predisposing factors in chronic rhinosinusitis specific to children:¹

- Day care, nasal obstruction and passive smoking are implicated.
- Breastfeeding does not appear to provide protection.
- Tonsillitis and otitis media increase the risk of sinusitis.
- Chronic rhinosinusitis is more common in children with mucociliary dysfunction due to cystic fibrosis (often with nasal polyps) and primary ciliary dyskinesia, and in those with humoral immune deficiencies.¹

If the mucociliary blanket malfunctions, secretions cannot be cleared, obstructing the outflow tract of the sinuses. Stasis of secretions leads to chronic infection. The most common bacteria observed in chronic rhinosinusitis are *Streptococcus pneumoniae*, *Haemophilus influenzae*, *Moraxella catarrhalis*, alpha-haemolytic streptococci, *Staphylococcus aureus*, and rarely, anaerobes.^{7,12}

Incidence

Prior to the introduction of the EPOS guidelines¹ and the practice parameter update on sinusitis diagnosis and management,³ the frequency of sinusitis was difficult to assess due to poor uniformity in diagnosis.

Children frequently have viral infections with sinonasal symptoms, with bacteria present 10-20% of the time. Sinusitis is often observed in children with allergic rhinitis, and 10-25% of children around the world are estimated to have allergic rhinitis.

The disease itself appears to be different to that in adults:¹

- The microbiology is typical of other upper respiratory tract infections in children.

- The paediatric immune response may still show an immature response to polysaccharide antigens.
- Disease in children tends to improve with age, while mature disease in adults shows little tendency to resolve spontaneously.
- Histology shows mainly neutrophilic disease, less basement membrane thickening and mucous gland hyperplasia, and more mast cells.
- Polyps are rare, except in cystic fibrosis.
- Generally a CT scan in a younger child shows a more diffuse pattern involving all sinuses, whereas in adults sphenoid and posterior ethmoids and frontals are less involved.

Symptoms of chronic rhinosinusitis in children

Rhinorrhoea, nasal obstruction, mouth breathing and cough are almost always present. Fever and pain are mostly absent. Recurrent purulent acute otitis media and otitis media with effusion are common in children.¹ (See Figure 2).

Figure 2: Symptom frequency in children with chronic sinusitis

Symptom	Types of rhinosinusitis
Rhinorrhoea (71-80%)	All forms
Cough (50-60%)	All forms
Fever (50-60%)	Acute
Pain (29-33%)	Acute
Nasal obstruction (70-100%)	Chronic
Mouth breathing (70-100%)	Chronic
Ear complaints (40-60%): recurrent purulent otitis media and effusion	Chronic

Clinical examination

Utilising these definitions, the clinical index of suspicion should be high before any further examination takes place.¹ Although regarded as being difficult, the examination (and consideration of the pathophysiology) can successfully lead to a diagnosis.

The nose

There is invariably significant chronic rhinitis, with erythematous mucosa; pale membranes support the allergy as a single diagnosis. Purulent secretions may be found within the nose, and depending on the ability of the examiner, may be detected in the middle meatus. Purulence alone does not indicate bacterial infection. Nasal endoscopy, if available, performed after topical anaesthesia, is not only the most accurate diagnostic tool, but is essential to exclude other conditions, such as polyps, foreign bodies, tumours and septal deviation, as well as to evaluate the adenoids. Accurate middle meatal sampling for bacteriology is also possible, and is almost equivalent to intrasinus sampling.

Outside the nose

In a child, the pharyngeal mucous membrane invariably mirrors the nasal mucosa. A diffuse red pharyngitis is commonly noted. Nodularity, representing lymphoid hyperplasia, is often present in chronic rhinosinusitis. The character and amount of post-nasal rhinorrhoea (drip) must be noted. Other lymphoid hyperplasia, tonsils (and adenoids), cervical lymphadenopathy (including posterior triangle), may also be seen. Lymphadenopathy is not usually tender in chronic rhinosinusitis. Unfortunately, many of these signs may be absent in children with chronic rhinosinusitis.

Microbiology in chronic rhinosinusitis

This is usually not evaluated, unless there are intracranial or orbital complications, or if the patient is immunocompromised. A general nasal swab has little correlation with sinus flora.

Imaging

Imaging is not necessary to confirm the diagnosis of uncomplicated rhinosinusitis in children. A CT scan of the sinuses is the modality of choice, where indicated. There is almost no place for standard radiology, as the marginal benefits are outweighed by the expense and drawback of radiation exposure.

Indications for a CT scan in children with chronic rhinosinusitis

- Planned surgery after failed, compliant maximum medical therapy;
- Intraorbital or intracranial complications;
- Immunocompromised.

Many children with CT scan evidence of chronic rhinosinusitis are asymptomatic. There is a high rate of resolution with age.

Treatment of chronic rhinosinusitis

Chronic rhinosinusitis in the young child does not have to be treated, as spontaneous resolution is probable. Complications of rhinosinusitis in a child are uncommon, especially if one considers the high incidence.

The data on specific treatment of chronic rhinosinusitis in children are limited. A quality of life tool for children, the SN-5, is available. Where the chronic rhinosinusitis is persistent and associated with troublesome symptoms, the following is pertinent.¹

Antibiotics

Antibiotics have modest benefits in the short and medium term.¹ For every eight children who are treated, one additional child will be cured. No long-term benefits were documented. Where antibiotic therapy is preferred, amoxicillin (45 mg/kg/day (doubled if under two years of age, or with risk

factors for resistance) is appropriate. β -lactamase cover for *M. catarrhalis* and *H. influenzae* infections should be considered. Local sensitivity data are essential for all clinicians. Appropriate step-up therapy is indicated for treatment failure after 72 hours. Macrolides are appropriate for penicillin-sensitive patients. At this time, two to six weeks of antibiotic therapy is indicated.¹

Topical corticosteroids

There are very little data describing the efficacy of topical corticosteroids in paediatric chronic rhinosinusitis. There are a large number of studies showing that local corticosteroids are effective and safe in children with rhinitis and acute rhinosinusitis. One may assume that the same is true for chronic rhinosinusitis.

Nasal douching

Both isotonic and hypertonic saline have some effect and are safe, reducing nasal secretions and oedema.¹

Gastro-oesophageal reflux therapy

Both improvement in chronic rhinosinusitis and reduction in need for surgery have been shown by adequately treating gastro-oesophageal reflux. Studies indicate that reflux should be evaluated and treated in children with chronic sinus disease before sinus surgical intervention.¹ Proton-pump inhibitor therapy should be the first choice, and if given in high doses, side-effects and complications must be monitored.

Local nasal decongestants

These reduce the nasal obstruction and can only be used for five to seven days. Dose issues can affect the very young. Paediatric formulations with appropriate dosing schedules are available. Long-term results may be no better than nasal douching for symptom reduction.¹

Other modalities

Studies with oral probiotic strains in sinusitis have shown some short-term improvement that is not sustained. Further longer term studies are required.¹³ There appears to be no convincing evidence for the use of any further medical treatments of chronic rhinosinusitis in children.

Surgical treatment of rhinosinusitis

In uncomplicated chronic rhinosinusitis, surgery should only follow a thorough investigation of underlying factors and a prolonged trial of medical therapy. Surgery includes adenoidectomy and functional endoscopic sinus surgery (FESS). Most uncomplicated cases would appear to benefit from adenoidectomy, with FESS reserved for adenoidectomy failures. Most controversy centres on the indications for FESS in children.¹

In 1998, international consensus was reached on the indications of FESS in children.¹ Absolute indications include:

- Complete nasal obstruction in cystic fibrosis due to massive polyposis or medialisation of the lateral nasal wall;
- Orbital abscess;
- Intracranial complications;
- Antrochoanal polyps;
- Mucocoele or mucopyocoele;
- Fungal rhinosinusitis.

Possible indications exist where frequent exacerbations persist, despite optimal, compliant medical management. After exclusion of any systemic disease, FESS is a reasonable alternative to continuous medical treatment. Optimal concurrent management includes two to six weeks of adequate antibiotics (intravenous or oral) with treatment of concomitant disease.

A lasting improvement in quality of life after surgery for rhinosinusitis has been reported. Overall quality-of-life scores show significant change after surgical therapy, regardless of whether adenoidectomy or FESS was performed. The domains with the most significant improvement were nasal obstruction and emotional distress. The domain with the least improvement was allergy symptoms.¹⁴

Younger age (< 7 years) and the presence of asthma appear to be indicators of adenoidectomy failure and the need for FESS.¹⁵ We favour deferring FESS until after failed adenoidectomy. Failing adequate medical therapy, FESS is safe and effective in chronic rhinosinusitis in children. When antibiotic therapy is warranted, the choice should be based on knowledge of antimicrobial resistance in specific geographic areas and populations. It is important to identify and treat predisposing factors, including viral upper respiratory infection, allergic rhinitis, nasal structural abnormalities, gastro-oesophageal reflux disease, and immune deficiencies.¹

Conclusion

Correct and accurate diagnosis of this distinct clinical entity is essential. The disease is multifactorial, and although therapies are effective in helping the majority of patients, a significant number result in incomplete resolution of the disease. Recurrence is not uncommon, highlighting current limitations in our understanding of this disorder.² Current research concentrates on a more comprehensive and basic understanding of chronic rhinosinusitis that is highly relevant to children (see Figure 3).

A dysfunctional host environment,⁴ including physical barrier defects, innate immune dysfunction, and activation of

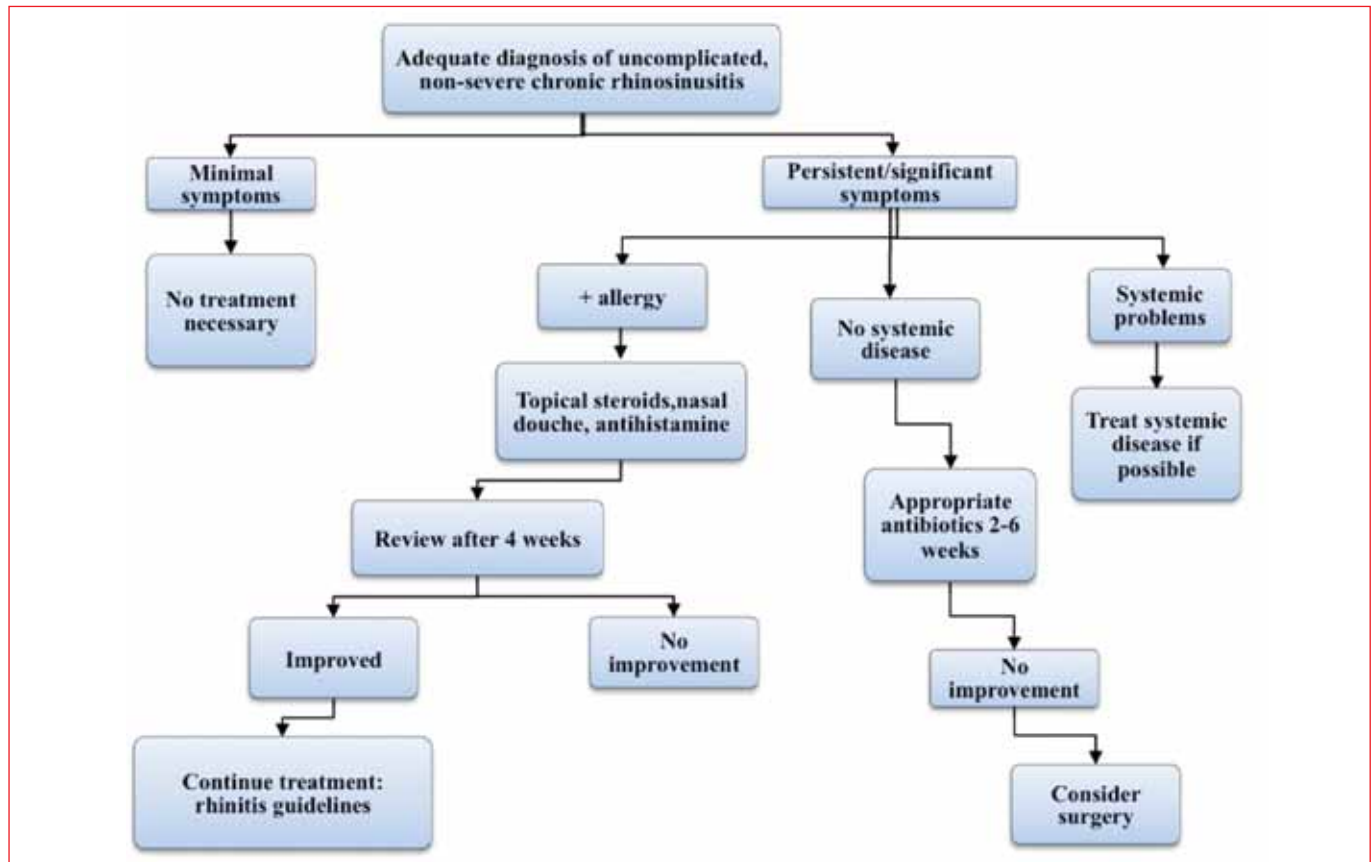


Figure 3: Management of uncomplicated, non-severe chronic rhinosinusitis in children¹

adaptive immunity through epithelial mediated mechanisms, can play a role in chronic rhinosinusitis:

- Biofilms.¹⁶
- Bacteria.¹
- Osteitis.¹
- Gastro-oesophageal reflux.¹

Time, adequate diagnosis and good evidence-based reporting will undoubtedly enable us to manage this very common condition more safely and reliably in the future.

References

1. Fokkens W, Lund V, Mullol J. European position paper on rhinosinusitis and nasal polyps. 2007. *Rhinology*; 45 (Suppl 20):1-139.
2. Bousquet J, Khaltaev N, Cruz AA, et al. Allergic rhinitis and its impact on asthma (ARIA) update (in collaboration with the World Health Organization, GA(2)LEN and AllerGen). 2008. *Allergy*. 2008;63:(Suppl 86):8-160.
3. Slavin G, Spector SL, Bernstein IL, et al. The diagnosis and management of sinusitis: a practice parameter update. *J Allergy Clin Immunol*, 2005; 116 (6 Suppl):S13-S47.
4. Tan BK, Schleimer R, Kern R. Perspectives on the aetiology of chronic rhinosinusitis. *Curr Opin Otolaryngol Head Neck Surg*. 2010;18(1):21-26.
5. Friedman RL, Hockman M. Chronic rhinosinusitis. *South Afr J Epidemiol Infect*. 2010;25(1):7-10.
6. Green RJ. Symptomatic treatment of upper respiratory tract symptoms in children. *SA Fam Pract*. 2006;48(4):38-42.
7. Brink AJ, et al. Updated guideline for the management of upper respiratory tract infections in South Africa. 2008. *South Afr J Epidemiol Infect*.
8. Messerklinger W. Endoscopy of the nose. Baltimore: Urban & Schwarzenberg Publishers;1978.
9. Wigand ME. Transnasal ethmoidectomy under endoscopic control. *Rhinology*. 1981;19(1):7-15.
10. Stammberger H. Endoscopic endonasal surgery: concepts in treatment of recurring rhinosinusitis. Part I. Anatomic and pathophysiologic considerations. *Otolaryngol Head Neck Surg*. 1986;94(2):143-147.
11. Porter G, Quinn FB. Paranasal sinus anatomy and function: Grand Rounds presentation, The University of Texas Medical Branch (UTMB), Department of Otolaryngology, 2002.
12. McClay JE. Paediatric sinusitis, surgical treatment: eMedicine [homepage on the Internet]. Available from: Medscape.com.
13. Mukerji SS, Pynnonen MA, Kim HM. Probiotics as adjunctive treatment for chronic rhinosinusitis: a randomised controlled trial. *Otolaryngology Head Neck Surg*. 2009;140(2):202-208.
14. Rudnik EF, Mitchell RB. Improvements in quality of life in children after surgical therapy for sinonasal disease. *Otolaryngology Head Neck Surg*. 2006; Vol. 134(5):737-740.
15. Ramadan HH, Tiu J. Failures of adenoidectomy for chronic rhinosinusitis in children: for whom and when do they fail? *Laryngoscope*. 2007;117(6):1080-1083.
16. Suh J, Cohen NA, Palmer JN. Biofilms in chronic rhinosinusitis. *Curr Opin Otolaryngol Head Neck Surg*. 2010;18(1):27-31.

