

Glaucoma: what should the general practitioner know?

Labuschagne MJ, MBChB, MMed(Ophth)(UFS)

Department of Ophthalmology (M1), School of Medicine, Faculty of Health Sciences, University of the Free State, South Africa

Correspondence to: Dr MJ Labuschagne, e-mail: mathyslab@mweb.co.za

Keywords: open angle glaucoma; angle closure glaucoma; congenital glaucoma; intraocular pressure; optic disc; algorithm for glaucoma

Abstract

Glaucoma is a sight-threatening condition. A general practitioner (GP) should be able to diagnose glaucoma, know about the different management options, and refer appropriately. The aim of this paper is to provide a background to glaucoma, and describe the assessment and management of glaucoma patients. The role of the GP in the management of glaucoma and in creating awareness of glaucoma is put into perspective.

© Peer reviewed. (Submitted: 2010-02-27, Accepted: 2010-08-09). © SAAFP

SA Fam Pract 2010;52(6):493-497

Introduction

Worldwide, glaucoma is the second most common cause of blindness, after cataracts.^{1,2} A conservative estimation of the prevalence of glaucoma in Africa is 4% of people in the age group > 40 years.² This age group comprises > 25% of the population of most African countries. In South Africa, the prevalence of all cases of glaucoma in this age group is between 4.5% and 5.3%^{3,4} and the proportion of blindness that can be attributed to glaucoma is 22.9%.⁵

Glaucoma causes irreversible damage to the optic nerve and no known treatment will restore lost vision. The most effective way of preventing damage to the optic nerve is to reduce the intraocular pressure (IOP) by means of various pharmacological and surgical interventions.

The ciliary body secretes aqueous humour into the posterior chamber, which then flows through the pupil and into the anterior chamber. The aqueous humour leaves the eye through the trabecular meshwork (a sieve-like structure), and flows into the Schlemm's canal and then into the episcleral veins. Overproduction or obstruction of drainage of aqueous humour may cause an increase in IOP, resulting in optic nerve damage.

The following is expected of a general practitioner (GP):

- Recognise the risk factors of glaucoma.
- Recognise the clinical manifestations of glaucoma, e.g. acute attack of angle closure glaucoma, and refer to an ophthalmologist for confirmation of the diagnosis, and treatment.
- Possess a basic knowledge of glaucoma medications and their systemic and local side effects, because the

family practitioner is often the first line of medical contact with the patient.

- Provide support, encouragement and counselling to the patient, because of the chronic course of the disease.
- Know how the normal day-to-day functioning of a glaucoma patient is influenced, e.g. reading, walking and driving.⁶
- Be aware that advanced glaucoma patients are prone to falls and bumping into obstacles, and that they have reduced outdoor mobility, especially in extreme lighting conditions (due to problems with glare, dark adaptation and peripheral vision).^{6,7,8}
- Educate patients about screening of family members, follow-up visits, and use of medication.

Diagnosis of glaucoma

Diagnosis of glaucoma depends on the presence of the following three components:

- Raised IOP (normal IOP is 10–21 mmHg).
- Structural damage to the optic nerve head (optic disc).
- Loss of visual field in a characteristic way.⁹

Assessment of patients with glaucoma

Assessment includes the measurement of the IOP, clinical evaluation of the optic disc, and a visual field evaluation. Different instruments can be used to measure the IOP. The Schiøtz tonometer (see Figure 1) is an indentation tonometer that can be used by GPs. The Goldmann applanation tonometer is the standard tonometer used by ophthalmologists and some optometrists. Most optometrists use an air-puff tonometer. An examination with

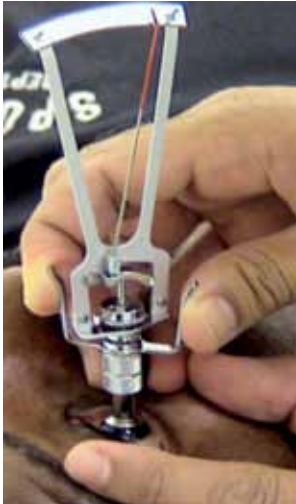

Figure 1: Schiotz tonometer

a direct ophthalmoscope gives an excellent view of the optic disc. The use of funduscopy and pupil reactions as screening tests for all persons at risk (age group > 40 years) have proved to be suitable screening tools for glaucoma.²

In a Cape Town study on African patients older than 40 years, it was found that visual acuity with a pinhole (6/18 or worse) in one or both eyes was a reliable tool for the detection of cataracts and glaucoma.² The sensitivity and specificity was > 90% and

the positive likelihood ratio was > 10.0. The use of direct ophthalmoscopy with a cut point of 0.7 vertical cup-to-disc ratio, in combination with pupil reactions, was suitable for case detection in glaucoma alone.²

Classification of glaucoma

The classification of glaucoma is outlined in Table I.¹⁰

Primary open angle glaucoma

Primary open angle glaucoma (POAG) is the most common form of glaucoma in South Africa, with a prevalence of 2.9%.⁴ In Ghana, the prevalence is as high as 8.5%.¹¹ POAG is a chronic, painless, progressive condition, and therefore the importance of early diagnosis depends on a medical practitioner.

POAG is defined by the European Glaucoma Society as a chronic, progressive optic neuropathy, causing characteristic morphological changes at the optic disc and retinal nerve fibre layer, in the absence of other ocular disease or congenital anomalies.⁹ The relative risk for POAG increases continuously with the level of IOP. There is, however, no evidence of a threshold IOP for the onset of POAG. The IOP alone cannot be used for diagnosis in the absence of other clinical features. The three components indicating glaucoma disease, IOP, optic disc and a visual field test, must be evaluated at regular intervals.^{9,10}

Table 1: Classification of glaucoma¹⁰

1. Primary open angle glaucoma (POAG)
 - Normal tension glaucoma (NTG)
 - Ocular hypertension (OHT)
2. Primary angle closure glaucoma (PACG)
3. Secondary glaucoma
4. Congenital glaucoma (CG)

Risk factors for developing POAG are given in Table II.

Table II: Risk factors for developing POAG

- Level of IOP^{1,4,5}
- Increasing age (the prevalence of glaucoma for persons < 40 years = rare; 40–60 years = 1%; 60–80 years = 2%; > 80 years = 4%)⁴
- African-Caribbean origin (5 x higher than Caucasians)^{1,4,5}
- Genetic make-up (first degree relatives of patients: 1 in 10)^{1,4,5}
- Diabetes mellitus^{1,4,5}
- Myopia^{1,4,5}
- Vascular factors (migraine; vasospastic disease; Raynaud's disease; hypotension and hypertension)⁴
- Thin corneas^{4,5}
- Retinal disease (retinal vein occlusion 5%; rhegmatogenous retinal detachment 3%; and retinitis pigmentosa)⁵

Clinical assessment of POAG

Symptoms

Pain is usually absent, and the patient is unaware of the condition. Loss of visual field is only noticed at a late stage, because the visual loss is gradual. Glaucoma patients with bilateral visual field loss have associated decline in motility and driving ability.⁶ Currently most patients with POAG are detected by optometrists at routine examinations. This highlights the missed opportunities in general practice offered by frequent encounters between GPs and patients, e.g. diabetics who may have risk factors.

Signs

On superficial examination, the eye is white and looks normal. The best tests for detection purposes include determination of optic disc changes and assessment of visual acuity with a pinhole, which can easily be carried out by primary health care workers.²

Optic disc changes

The cup-to-disc ratio increases as the nerve fibres undergo atrophy (excavation). Blood vessels may bend sharply backwards ("bayoneting")^{12,13} and are usually displaced nasally. Asymmetry of the cupping is important, as the disease is often more advanced in one eye than the other. Haemorrhage at the optic disc or at the margin is a sign of disease progression. Use of serial fundus photographs is a good way to detect progression.^{14,15} Figures 2 and 3 show glaucomatous optic discs.

Visual field defects

Visual field defects are difficult to detect clinically without specialised equipment until late in the disease (loss of > 50% of the nerve fibres).

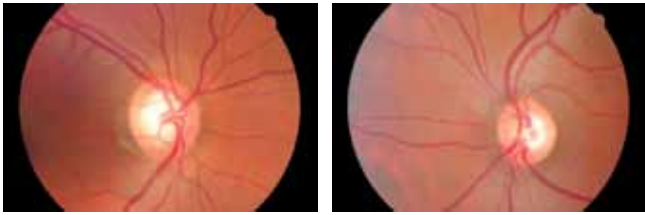


Figure 2: Glaucomatous optic discs

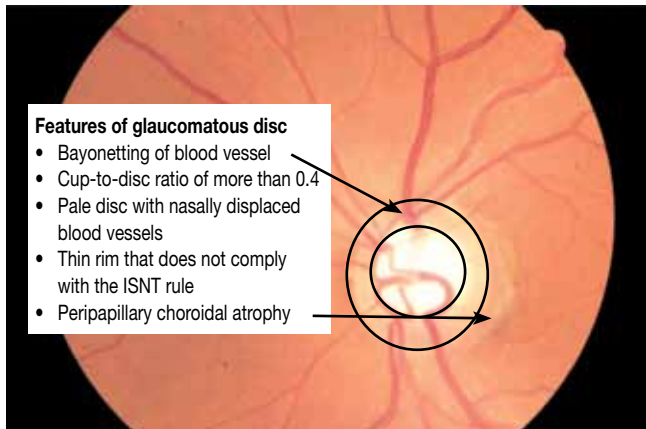


Figure 3: Photograph showing features of a glaucomatous optic disc

Intraocular pressure

IOP measurements alone are not adequately sensitive for screening for glaucoma.^{9,10,16} Many normal individuals have an IOP consistently above 21 mmHg and yet never develop optic disc atrophy or visual field defects (ocular hypertension).^{9,10,17} Similarly, up to one third of patients with glaucoma will have an IOP < 21 mmHg at the time of screening, and will, therefore, go undiagnosed (normal tension glaucoma).^{9,10,18} If the IOP is > 21 mmHg, there is a 5% likelihood, and if the IOP is > 39 mmHg, there is a 90% likelihood of developing glaucoma.¹²

Table III gives a few tips to the GP when screening for glaucoma.

Table III: Practical tips when screening for glaucoma

- Optic disc examination with an ophthalmoscope is particularly useful when screening for glaucoma in a family practice.
- IOP higher than 21 mmHg with Schiottz tonometer should be referred to an ophthalmologist.
- The prevalence of glaucoma in South Africa in people over the age of 40 years ranges from 3 to 5% in whites and 5 to 7% in black and coloured patients.³
- When performing routine medical examinations (e.g. ECG, Pap smears, cholesterol) on persons older than 40 years, one should **always** do a fundoscopy to check for glaucomatous changes of the optic disc, and measure the IOP to screen for glaucoma.

Angle closure glaucoma

Primary angle closure glaucoma (ACG) is caused by appositional or synechial closure of the anterior chamber angle, due to a number of mechanisms.⁹ This is a sight-threatening emergency, involving painful loss of vision, due to sudden and total closure of angle. It is probably the best known type of glaucoma. In ACG, apposition of the lens to the back of the iris prevents the flow of aqueous humour from the posterior chamber to the anterior chamber.⁹ This is more likely to occur when the pupil is semi-dilated at night. Aqueous humour that collects behind the iris pushes the iris onto the trabecular meshwork, preventing the drainage of the aqueous humour from the eye, and resulting in a rapid increase in IOP.

Symptoms

Symptoms of an acute attack are a painful red eye, headache and, frequently, nausea and vomiting. Vision is blurred, because the cornea becomes oedematous. There may be a history of similar attacks in the past that were aborted by going to sleep, because the pupil constricts and may pull the peripheral iris out of the angle, ending the attack. Table IV gives a summary of the groups of patients with a higher risk for developing ACG.

Table IV: Groups at risk of developing acute ACG

- Hypermetropic (far-sighted) patients^{4,7}
- Women (3–4 times higher)^{4,7}
- Eskimos (40 times higher) and Asians have a higher incidence than Caucasians^{4,7}
- Black patients have a low risk for developing ACG^{4,7}
- Highest incidence: 55–65 years of age⁴
- People of mixed racial ancestry in Cape Town, South Africa¹⁶

Signs

- Impaired visual acuity
- Red and painful eye
- Cornea is hazy, because of the oedema
- Pupil is semi-dilated and fixed, with no reaction to light
- On palpation, the affected eye feels harder than the other eye
- The eclipse sign is positive, indicating a shallow anterior chamber
- Systemic signs are nausea, vomiting or headache

If the patient is seen shortly after an attack has resolved, none of these signs may be present. Therefore it is important to take a good history.

Medical treatment for the acute attack^{1,12,13,19,20}

- Acetazolamide (Diamox®) 500 mg IV or per os
- Hyperosmotic agents, e.g. glycerine or mannitol

- Topical miotics, e.g. pilocarpine 2%, to constrict the pupil and pull the iris from the trabecular meshwork
- Analgesics
- Antiemetics
- Lie supine for one hour so that the effect of gravity can pull the iris from the angle.

Surgery

Surgery is the treatment of choice for ACG and is performed as soon as the cornea has cleared after the acute attack. A peripheral iridectomy or laser iridotomy can be performed. Both eyes are treated, because the risk of angle closure in the other eye is significant.¹³

Prophylactic treatment

Pilocarpine drops can prevent an acute attack until the patient can be referred for surgery or laser treatment.²⁰

Secondary glaucoma

In secondary glaucoma elevated IOP results in progressive optic disc neuropathy and visual field defects. The condition is caused by other ophthalmological or extraocular diseases and certain drugs. The GP must be aware of the underlying pathology that may cause secondary glaucoma, in order to prevent or delay the progression of glaucoma.

The most common causes of secondary open angle glaucoma include the following^{12,13,14}:

- Treatment with steroids (topical and systemic, asthma inhalers, nasal sprays, and even topical ointments)
- Particles that block the trabecular meshwork (malignant cells, red blood cells, inflammatory cells or pigment)
- Membranes in the anterior chamber angle
- Trauma to the trabecular meshwork
- Neovascularisation in the angle, e.g. in diabetics, or after central retinal vein occlusion
- Pseudoexfoliation syndrome⁴

Congenital glaucoma

In congenital glaucoma (CG), a developmental malformation of the anterior chamber angle causes glaucoma. CG calls for early assessment and surgical intervention to prevent structural damage to the optic disc and allow visual development.⁹ CG is frequently bilateral and associated with other defects. It needs early diagnosis to avoid irreversible blindness.

The symptoms include severe photophobia, blepharospasm and lacrimation. The signs that a GP should look out for include corneal haze, corneal opacity, increased corneal diameter (> 12 mm), increased size of the eye or buphthalmos (due to raised IOP and elastic sclera), and a pale optic disc.

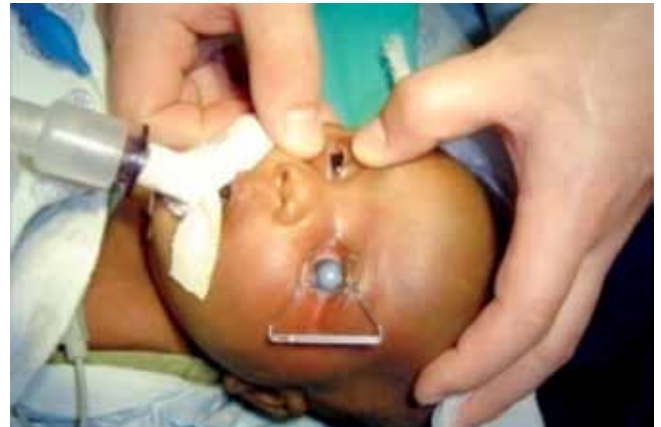

Figure 4: Congenital glaucoma in the left eye of a baby with Sturge-Weber syndrome

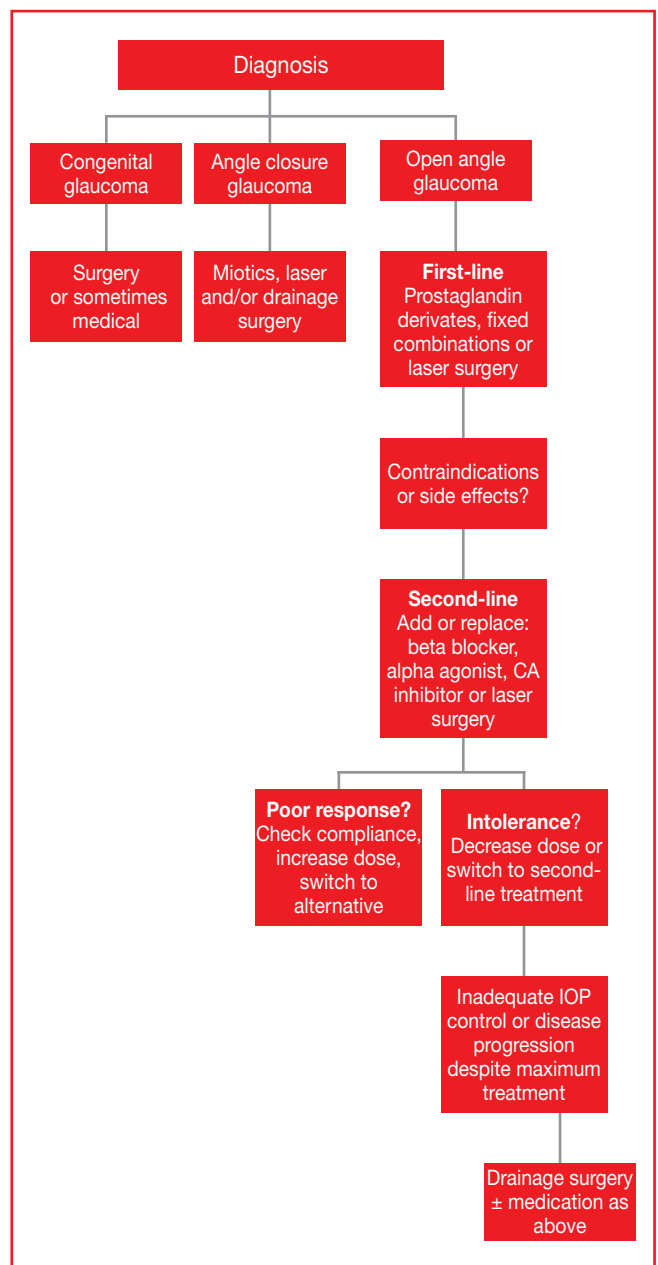


Figure 5: Algorithm for glaucoma¹⁰

Treatment

Treatment involves surgery (goniomy or trabeculotomy)

South Africa Glaucoma Society algorithm for the management of glaucoma (Figure 5)

In 2009 the South African Glaucoma Society (SAGS) released an updated treatment algorithm and guidelines for glaucoma to the Council for Medical Schemes to improve the understanding of glaucoma diagnosis and management. This provides a rational approach to the diagnosis and management of glaucoma, based on evidence from prospective randomised clinical trials. The document has been endorsed by the Ophthalmological Society of South Africa.

The main change in approach is that management starts with prostaglandin analogues, and combinations, and the former first-line drugs have now been moved to second-line treatment.

Conclusion

The role of the GP in the diagnosis and treatment glaucoma

- Identify patients with signs and symptoms suggestive of acute, angle closure glaucoma and institute management, in addition to referral to the ophthalmologist.
- Engage in screening of patients with symptoms and signs suggestive of open angle glaucoma.
- Explain and reassure the patient, because this is a chronic condition.²¹
- Bilateral glaucoma is associated with driving cessation and limitation, bumping into objects and falls.^{6,7} Therefore, the GP should discuss the impact of the visual loss with patients and their families.⁶
- Monitor therapy²¹:
 - Beta blockers can cause postural hypotension, bronchospasm and worsening of asthma, impotence, heart block and congestive cardiac failure.
 - Topical allergy to the drug, or the preservative in the drops, can cause itching, swelling of eyelids and eczema of the periocular skin.
 - Side effects of acetazolamide (Diamox®) can include nausea, paraesthesia, electrolyte disturbances and renal stones.
 - Prostaglandins can cause an increase in melanin pigmentation in the iris, blurred vision, redness of the eyelids and anterior uveitis, upper respiratory tract infection symptoms, chest pain and miscarriages.
- Review repeat prescriptions for medical schemes, preferably six monthly.²¹
- Refer for reassessment if the patient has symptoms of progression or side effects from the treatment.²¹

- Educate patients about screening of family members and the genetic factors in glaucoma. (First degree relatives have a 10% chance of developing glaucoma.)^{1,12,13}
- Refer a patient who has had previous glaucoma surgery (even years before), and who presents with a red eye or signs of infection, back to the ophthalmologist immediately, to exclude blebitis or endophthalmitis.²¹

References

1. Khaw PT, Shah P, Elkington AR. ABC of eyes. 4th edition. Spain: BMJ Books; 2004.
2. Cook CD. Glaucoma in Africa. Size of the problem and possible solutions. *J Glaucoma* 2009;18(2):124–8.
3. Rotchford AP, Johnson GJ. Glaucoma in Zulul – a population-based cross-sectional survey in a rural district in South Africa. *Arch Ophthalmol* 2002;120:471–8.
4. Rotchford AP, Kirwan JF, Muller MA, Johnson GJ, Roux P. Temba glaucoma study – a population-based cross-sectional survey in urban South Africa. *Ophthalmology* 2003;110(2):376–82.
5. Cook CD, Knight SE, Crofton-Briggs I. Prevalence and causes of low vision and blindness in northern KwaZulu. *S Afr Med J* 1993;78:275–9.
6. Ramulu P. Glaucoma and disability: which tasks are affected, and at what stage of disease? *Curr Opin Ophthalmol* 2009;20(2):92–8.
7. Spaeth G, Walt, Keener J. Evaluation of quality of life for patients with glaucoma. *Am J Ophthalmol* 2006;141(1 Suppl):S3–14.
8. Nelson P, Aspinall P, Papasouliotis O, Worton B, O'Brien C. Quality of life in glaucoma and its relationship with visual function. *J Glaucoma* 2003;12(2):139–50.
9. European Glaucoma Society (EGS). 2003. Terminology and guidelines for glaucoma. Available from www.eugs.org (Accessed 27-02-2010).
10. South African Glaucoma Society. 2009. Glaucoma algorithm and guidelines for glaucoma. Available from www.sags.com (Accessed 27-02-2010).
11. Ntim-Amponsah CT, Amoaku WM, Ewusi RK, Idirisuriya-Khair R, Nyatepe-Coo E, Ofosu-Amaah S. Evaluation of risk factors for advanced glaucoma in Ghanaian patients. *Eye* 2005;19:528–34.
12. Rhee DJ. Glaucoma: colour atlas & synopsis of clinical ophthalmology – Wills Eye Hospital. 1st edition. McGraw-Hill: USA; 2003, p. 103–17, 210–5, 230–71.
13. Kanski JJ. 2007. Clinical ophthalmology: a systemic approach. 6th edition. China: Butterworth Heinemann.
14. Flammer J, 2006. Glaucoma: a guide to patients. 3rd edition. Hogrefe.
15. Leske MC, Heijl A, Hussein M, Bengtsson B, Hyman L, Komaroff E. Factors for glaucoma progression and the effect of treatment: the early manifest glaucoma trial. *Arc Ophthalmol* 2003;121:48–56.
16. Salmon JF, Mermoud A, Ivey A, Swanevelde SA, Hoffman M. The prevalence of primary angle closure and open angle glaucoma in Mamre, Western Cape, South Africa. *Arch Ophthalmol* 1993;111:1263–9.
17. Kass MA, Heuer DK, Higginbotham EJ, et al. The ocular hypertension treatment study. a randomized trial determines that topical ocular hypotensive medication delays or prevents the onset of POAG. *Arch Ophthalmol* 2002;120:701–3.
18. The effectiveness of intraocular pressure reduction in the treatment of normal tension glaucoma. Collaborative Normal Tension Glaucoma Study Group (No authors listed). *Am J Ophthalmol* 1998;126:498–505.
19. Tsai JC, Tello C, Ritch R. Angle closure glaucoma update. *Focal Points- Clinical Modules for Ophthalmologists* 2009; volume 27 issue 6 module 3 of 3:1–14.
20. Stulting AA. Pharmacotherapy in ophthalmology. *CME* 1994:189–204.
21. Salmon J.F. *CME/VMO Glaucoma for the GP*. 1994;179–87.