

# The pleural effusion in HIV – an approach to diagnosis

Mostert C, MMed(Int)

Pannell N, MMed(Int)

Department of Internal Medicine, University of Pretoria and Steve Biko Academic Hospital

Correspondence to: Dr Chris Mostert, e-mail: mostert@icon.co.za

Keywords: HIV, pleural effusion

## Abstract

HIV is one of the most prevalent diseases and causes of mortality in sub-Saharan Africa. Pleural disease is common in the population of this region, especially pleural effusion. The disease is associated with a significant mortality rate, and correct diagnostic and therapeutic management is essential to optimising the possibility of a favourable outcome.

SA Fam Pract 2009;51(4):280-282

## Introduction

No formal comprehensive data is available regarding the epidemiology of the human immunodeficiency virus (HIV) in South Africa. However, HIV infections among pregnant South African women are common, with one report indicating a prevalence of 29.5% in an antenatal clinic programme.<sup>1</sup> The burden of HIV in South Africa is apparent in day-to-day clinical practice, with an estimated contribution to mortality in this country of 26% of all causes of death.<sup>2</sup> As such, the occurrence of a pleural effusion in HIV/AIDS patients is common – pleural effusions are frequently encountered in patients with the acquired immunodeficiency syndrome (AIDS) – and one study found pleural effusions in 59 of 222 (27%) of hospitalised patients with AIDS.<sup>3</sup> HIV in itself can record a lower prevalence of associated pleural effusion – another study of all HIV hospitalised patients found a prevalence of 14 % for pleural effusions.<sup>4</sup> The differences in prevalence can be explained by the stage of HIV infection (the advanced disease, common in South Africa, is associated with effusion).<sup>5</sup> The mortality rates associated with pleural effusion range between 10% and 40%, as described by Afessa in a review article on the causes of disease in pleural effusion in HIV patients and in research by Soubani and colleagues.<sup>6,7</sup>

## Initial approach

A pragmatic approach to the analysis of a pleural effusion in these patients can assist in making an accurate diagnosis and aid in definitive treatment.<sup>8</sup> The methodology suggested in this article follows the standard acceptable approach to a pleural effusion while incorporating features that are more specific to HIV, following a review of articles found via a MEDLINE search.<sup>9</sup> The collection of pleural fluid for analysis should be the first step since it is relatively simple and methods of collection have been well described (including the use of ultrasound guided thoracentesis).<sup>8</sup> The standard initial approach to an effusion is suggested using Light's criteria<sup>9</sup>:

Pleural fluid protein/serum protein > 0.5

Pleural fluid LDH/serum LDH > 0.6

Pleural fluid LDH more than two-thirds of the normal upper limit for serum

Exudative pleural effusions meet at least one of the above-mentioned criteria (two criteria are more specific for an exudate).

After determining whether a transudate or exudate is present, an initial differential diagnosis can be postulated (see Table I).

**Table I: Most common causes of a pleural effusion in HIV**

Transudate	Exudate
Heart failure (including HIV-associated cardiomyopathy)	Parapneumonic effusions Tuberculosis
HIV-associated hypo-albuminaemia	Other infections (see text)
Nephropathy (HIV-associated nephropathy)	Empyema
Chronic liver disease	Kaposi's sarcoma
Pulmonary embolism	Lymphoma Pulmonary embolism Pancreatitis

## The transudate

The cause of a transudative state should be clear after clinical and basic laboratory assessment for cardiac disease, proteinuria and chronic liver disease. An aggressive course of liver disease occurs in HIV patients where co-infection is present with a hepatotropic virus, e.g. Hepatitis B or C.<sup>10</sup> Cardiomyopathy related to HIV has been proven to be present in up to 24% of these patients.<sup>11</sup> HIV nephropathy is estimated to be present in 10% of patients with HIV.<sup>12</sup> Hypo-albuminaemia has been associated with HIV infection and might have prognostic value as well.<sup>13</sup>

## The exudate

### Parapneumonic effusion

The parapneumonic effusion is the most common cause of an effusion in this population of patients, accounting for approximately 50% of

such effusions.<sup>6</sup> Evidence of pneumonia is readily apparent on a chest radiograph and the pathogens involved include *S pneumoniae*, *S aureus*, *H Influenzae* and *Pseudomonas auruginosa*.<sup>14</sup>

*Pneumocystis jiroveci* is seldom the cause of a pleural effusion, accounting for only 4% of effusion in HIV patients.<sup>5</sup>

### Empyema

Empyema causes 1% of pleural effusions in patients with HIV.<sup>5</sup> Factors that would be indicative for a more invasive procedure (e.g. intercostal drain) rather than a thoracentesis alone would include the following:<sup>9</sup>

1. Loculated pleural effusion
2. Pleural fluid < pH 7.2
3. Pleural fluid glucose < 3.3 mmol/l
4. Positive gram stain or culture of the pleural fluid
5. Presence of gross pus in the pleural space

### Tuberculous pleural effusion

Following bacterial pneumonia, tuberculous effusions are the most common cause of pleural effusion in patients with HIV.<sup>5</sup>

The gold standard for the diagnosis of pulmonary tuberculosis in the pleural fluid would be the demonstration of mycobacteria. However, a pleural fluid stain and culture is positive in 33 to 91% of tuberculosis cases while a pleural biopsy smear for acid fast bacilli (AFB) is positive in 44 to 69% of tuberculosis cases.<sup>16,17</sup> Pleural fluid ADA (adenosine deaminase) is a cost-effective alternative and exhibits good sensitivity and specificity as regards this population: A pleural fluid ADA level of 55 or more or in combination with a lymphocyte neutrophil ratio of 0.75 or greater gives a sensitivity of 88% and specificity of 95%.<sup>18</sup> However, in a study examining the value of ADA in the diagnosis of tuberculous effusion in HIV-positive patients specifically, a pleural fluid value of 60 or more has been proven to have a sensitivity of 95% and specificity of 96%. Raised levels are also associated with other conditions, including malignancies (especially lymphoma), bacterial infections, empyema and connective tissue diseases (less common in patients with HIV).<sup>18</sup> The guiding principle would be to commence a therapeutic trial of anti-tuberculosis therapy if these mentioned causes have provisionally been excluded. In the absence of positive tuberculosis, smear therapy can safely be initiated while awaiting culture results – this method has been proven to be efficacious in South Africa in a smear-negative protocol for HIV patients where a high clinical index of suspicion of tuberculosis is present.<sup>19</sup> In the event that clinical progress is not satisfactory or the culture is negative, other conditions that can raise the ADA or cause an exudate must be reconsidered.

### Other infections

Other infective causes of a pleural effusion include: *Mycobacterium avium complex*, *Cytomegalovirus*, *Aspergillus species*, *Cryptococcus neoformans*, *Nocardia species*, *Leishmania donovani*, *Toxoplasmosis gondii* and *septic emboli* (especially in intravenous drug abusers).<sup>5</sup>

### Malignancies

#### Kaposi's sarcoma

In total, 47 to 75% of HIV-infected patients with cutaneous Kaposi's sarcoma have pleuropulmonary involvement, and 60% of these patients present with a pleural effusion.<sup>5</sup> Patients with pulmonary Kaposi's sarcoma can, on occasion, present without mucocutaneous involvement.<sup>20</sup>

The diagnosis of Kaposi's sarcoma is suggested by bilateral pleural effusions, usually large to massive in size.<sup>22</sup> Most effusions are bloody or blood-tinged.<sup>23</sup> The chest x-ray may identify lymphadenopathy and/or intrapulmonary nodules.<sup>24</sup>

Pleural fluid characteristics are as follows:

- pH mostly greater than 7.44
- mononuclear cell predominance
- LDH between 111 and 330 IU/L
- Glucose concentration > 3.3 mmol/l<sup>21</sup>

Cytological examination of the fluid is unrewarding.<sup>25</sup> A percutaneous pleural biopsy cannot confirm the diagnosis of Kaposi's sarcoma as the lesions are not found on the parietal pleura.<sup>21</sup>

An open-lung biopsy confirms the diagnosis in 75% of cases, but owing to the risk/benefit ratio this procedure is of limited value.<sup>26</sup> The characteristic cherry-red endobronchial lesions found on bronchoscopy, in the proper clinical setting, establish the diagnosis of Kaposi's sarcoma.<sup>5,24</sup>

Human herpes virus 8 (HHV-8) is implicated in the pathogenesis of Kaposi's sarcoma.<sup>27</sup> HHV-8 DNA in broncho-alveolar lavage has a high sensitivity (100%) and specificity (98.9) for pulmonary involvement of Kaposi's sarcoma.<sup>28</sup>

### Lymphoma

HIV infection is frequently complicated by non-Hodgkin's lymphoma (NHL),<sup>25</sup> with pulmonary involvement in 1 to 14% of cases. Pleural effusions are common and occur in 68% of thoracic NHL in patients with AIDS.<sup>5</sup> Lymphoma-related effusions are usually small and bilateral.<sup>24</sup> It is important to note that primary pulmonary lymphomas present without pleural effusions.<sup>5</sup>

Pleural fluid analysis may show low glucose and elevated red and white cell counts.<sup>5</sup> Pleural fluid cytology records a wide variation in rates of positive findings in NHL (22.2 – 94%).<sup>29</sup>

In the study by Eisner et al, closed pleural biopsy recorded a yield of 100% and open-lung biopsy 75% in the diagnosis of pulmonary lymphoma.<sup>30</sup>

Cyodiagnosis of malignant lymphoma can be very difficult, but various ancillary studies, including immunocytochemistry, morphometry, flow cytometry and cytogenetics/molecular genetics are available for establishing the diagnosis.<sup>29</sup>

### Primary effusion lymphoma

Primary effusion lymphoma (PEL) is characterised by its predilection for body cavities such as the pleural space.<sup>5</sup> PEL accounts for less than 4% of AIDS-related lymphomas<sup>31</sup> and occurs with less severe immunodeficiency than the other NHLs.<sup>32</sup>

Radiographic studies in PEL show pleural effusions without any lymphadenopathy, detectable mass or parenchymal abnormalities. Pericardial or peritoneal effusions may also be present.<sup>5</sup>

Pleural fluid cytology is almost always positive for malignant cells.<sup>5</sup>

The malignant cells contain genetic material from HHV-8 and in some cases Epstein's bar virus. A polymerase chain reaction test on pleural fluid will aid in the diagnosis of primary effusion lymphoma.<sup>5</sup>

### Less common causes of an exudate

Less common causes that need to be considered if a diagnosis has not been reached are those of pancreatitis and pulmonary embolism.<sup>5</sup> A pulmonary embolism can present as either an exudate or transudate.<sup>32</sup>

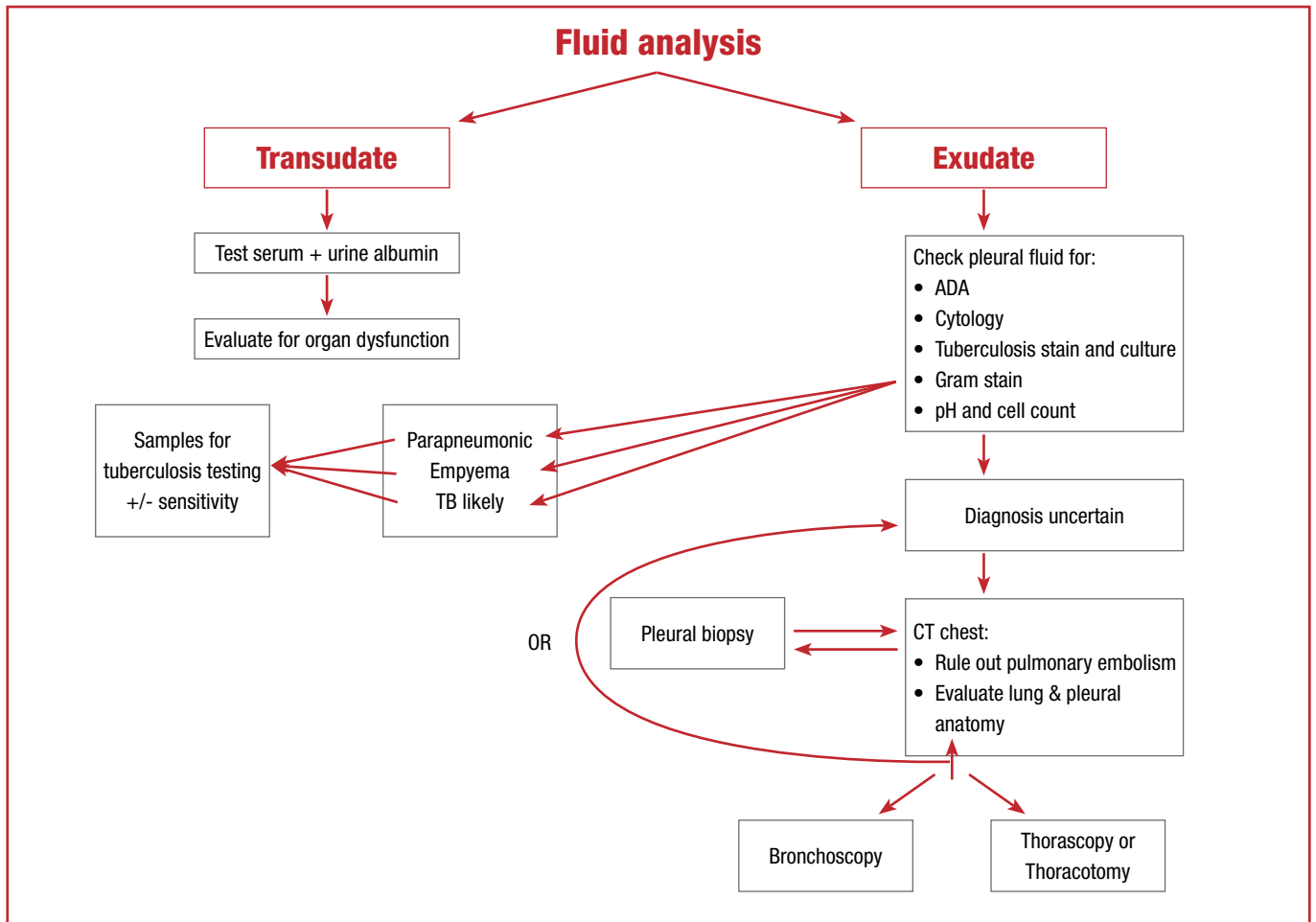


Figure 1: Suggested guide to an effusion in an HIV-positive patient (depending on available resources)

### Conclusion

Although pneumonia and tuberculosis account for the majority of pleural effusions in HIV patients, the clinician must take into account that while HIV is prevalent in our country, and is associated with significant mortality, other causes of an effusion will be present in some patients and therefore a high index of suspicion with respect to the differential diagnosis of any pleural effusion in this population is required to avoid a missed diagnosis. A flow diagram (Figure 1) compiled by the authors can be used as a guide to evaluate a pleural effusion in HIV patients.

### Acknowledgements

The authors would like to thank Dr David Levey (Department of English Studies, UNISA) for his linguistic review of this article.

### References

- National HIV and Syphilis Antenatal Sero-Prevalence Survey in South Africa 2004. Available from <http://www.hst.org.za/publications/675> (Last accessed 24/07/2008).
- Johnson L, Bradshaw D, Dorrington R. The burden of disease attributable to sexually transmitted infections in South Africa in 2000. *SAMJ* 2007;197(8):658-62.
- Joseph J, Strange C, Sahn SA. Pleural effusions in hospitalized patients with AIDS. *Ann Int Med* 1993;118:856-861.
- Armbruster C, Schalleschak J, Vetter N, Pokiesler L. Pleural effusions in human immunodeficiency virus-infected patients. *Acta Cytologica* 1995;39:698-701.
- Afessa B. Pleural effusions and pneumothoraces in AIDS. *Curr Opin Pulm Med* 2001;7:202-109.
- Afessa B. Pleural effusion and pneumothorax in hospitalized patients with HIV infection. *Chest* 2000;117:1031-7.
- Soubani AO, Michelson MK, Kamik A. Pleural fluid findings in patients with AIDS: Correlation with concomitant pulmonary disease. *South Med J* 1999;92:400-3.
- Light RW. Disorders of the pleura and mediastinum. *Harrison's principles of internal medicine*. 17th edition. McGraw Hill. New York. 2008:1658-60.
- Feller-Kopman D. Therapeutic thoracentesis: The role of ultrasound and pleural manometry. *Curr Opin Pulm Med* 2007;13:312-315.

- Puoti M, Torti C, Bruno R, Filice G, Carosi G. Natural history of chronic hepatitis B in co-infected patients. *J Hepatol* 2006;44:S65-67.
- Roy VP, Prabhakar S, Pulvirenti J, Mathew J. Frequency and factors associated with cardiomyopathy in patients with human immunodeficiency virus infection in an inner-city hospital. *J Natl Med Assoc* 1999;91:502-503.
- Tejinder S, Ahuja TS, Borucki M, et al. Is the prevalence of HIV-associated nephropathy decreasing? *Am J Nephrol* 1999;19:655-9.
- Mehta SH, Astemborski J, Sterling TR, Thomas DL, Vlahov D. Serum albumin as a prognostic indicator for HIV disease progression. *AIDS research and human retroviruses*. 2006;22(1):14-21.
- Afessa B, Green B. Bacterial pneumonia in hospitalized patients with HIV infection: The pulmonary complications, ICU support and prognostic factors of hospitalized patients with HIV (PIP) study. *Chest* 2000;117:1017-22.
- Gil V, Cordero PJ, Greses JV, Soler JJ. Pleural tuberculosis in HIV-infected patients. *Chest* 1995;107:1775-1778.
- Frye MD, Pozsik CJ, Sahn SA. Tuberculous pleuritis and HIV disease. *Chest* 1995;108:101-102S.
- Relkin F, Aranda CP, Garay SM, et al. Pleural tuberculosis and HIV infection. *Chest* 1994;105:1338-1345.
- Burgess LJ, Leroux I, Taljaard JF. Combined use of pleural adenosine deaminase with lymphocyte/neutrophil ratio. *Chest* 1996;109:414-9.
- Saranchuk A, Boulle A, Hildbrand K, Coetzee D, Van Cutsem G, Meintjies G. Evaluation of a diagnostic algorithm for smear-negative pulmonary tuberculosis in HIV-infected adults. *SAMJ* 2007;97(7):517-23.
- O'Brien RF. Pulmonary and pleural Kaposi's sarcoma in the acquired immune deficiency syndrome. *Semin Respir Med* 1989;10:12-18.
- Moskowitz LB, Hensley GT, Gould EW, Weis SK. Frequency and anatomic distribution of lymphadenopathic Kaposi's sarcoma in the acquired immunodeficiency syndrome. *Hum Pathol* 1985;16:447-454.
- O'Brien RF, Cohn DL. Serosanguineous pleural effusions in AIDS-associated Kaposi's sarcoma. *Chest* 1989;96:460-6.
- Miller RF, Howling SJ, Reid AJ, Shaw PJ. Pleural effusions in patients with AIDS. *Sex Transm Inf* 2000;76:122-5.
- Soubani AO, Michelson MK, Kamik A. Pleural fluid findings in patients with the acquired immunodeficiency syndrome: Correlation with concomitant pulmonary disease. *South Med J* 1999;92(4):400-3.
- Judson MA, Shan SA. Endobronchial lesions in HIV infected individuals. *Chest* 1994;105:1314-1318.
- Bryant-Greenwood P, Sorbara L, Filie AC, et al. Infection of mesothelial cells with human herpes virus 8 in human immunodeficiency virus-infected patients with Kaposi's sarcoma, Castleman's disease and recurrent pleural effusion. *Mod Pathol* 2003;16(2):145-53.
- Tamm M, Reichenberger F, McGandy CE, et al. Diagnosis of pulmonary Kaposi's sarcoma by detection of human herpes virus 8 in bronchoalveolar lavage. *Am J Respir Crit Care Med* 1998;157:458-464.
- Das DK. Serous effusions in malignant lymphomas: A review. *Diagnostic Cytopathology* 2006;34(5):335-47.
- Eisner MD, Kaplan LD, Herndier B, Stulberg MS. The pulmonary manifestations of AIDS-related non-Hodgkin's lymphoma. *Chest* 1996;110(3):729-36.
- Chen YB, Rahemtullah A, Hochberg E. Primary effusion lymphoma. *Oncologist* 2007;12(5):569-76.
- Mbulaitaye SM, Biggar RJ, Goedert JJ, Engels EA. Pleural and peritoneal lymphoma among people with AIDS in the United States. *JAIDS* 2002;29(4):418-20.
- Sahn SA. State of the art. The pleura. *Am Rev Respir Dis* 1988;138:184-190.