

HEART MURMURS IN CHILDREN

Are you too quick to refer?

Many children with murmurs are unnecessarily referred, say the authors, who describe a thorough cardiovascular exam you can perform in three to five minutes.

By B S Alpert, MD, and W B Stong, MD

Hear murmurs are among the most common physical findings in children.

Murmurs are nothing more than noises, and the vast majority are normal.

At some time in their lives all children have a heart murmur; therefore, any physician dealing with children must be able to discern what is normal before abnormal sounds can be differentiated.

There are other reasons for being able to evaluate a child with a heart murmur. First, the cost of a complete evaluation by a cardiac specialist and that doesn't include the parents' time lost from work, travel expenses to the medical centre, and other professional costs, including laboratory procedures.

When all these expenses are added together, the toll becomes high indeed.

Another reason to evaluate a murmur yourself is to reduce the psychological cost to the family. If parents are told that their child has a heart murmur, and the primary-care physician is not sure whether it is normal, the entire family faces days or even weeks of anxiety until a specialist makes his evaluation.

This can be an extremely trying time for the family.

In order to detect abnormal mur-

murs, you must perform a complete and routinized cardiovascular examination, using inspection, palpation, and auscultation.

Always remember, however, that you will often discover murmurs in many otherwise normal children whom you see for routine checkups and for self-limited illness, especially febrile diseases.

Inspection

Look for distress, cyanosis

The general appearance of the child is important. Note such crucial physical signs as respiratory distress, edema, cyanosis, and clubbing of the nails. Any of these obvious signs calls for further investigation.

In addition, take the heart rate and rhythm, respiratory rate and pattern, blood pressure of the upper and lower extremities, and percentiles of height and weight.

You should also look for physical signs that suggest genetic syndromes (Marfan's, Down's, or Turner's) because of their frequent association with cardiovascular abnormalities.

Palpation

A peripheral-to-central method

Palpation is the next routine step in the cardiac evaluation. We

generally use a peripheral-to-central approach, including palpation of the peripheral pulses, the femoral and brachial arteries, the abdominal viscera, and finally the precordium.

Palpate the peripheral pulses to determine the presence or absence of pulses and the pulse pressure; this is especially important in aortic stenosis, where there is a small pulse pressure, or patient ductus arteriosus, which has a wide pulse pressure.

The femoral and brachial arteries should be palpated simultaneously.

Absence of or a decrease in the femoral pulse is the best means of detecting coarctation of the aorta.

Moving more centrally, palpate the abdominal viscera, especially the liver and spleen.

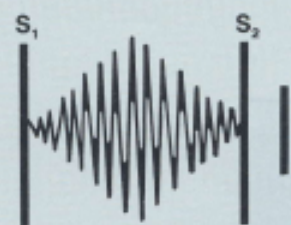
This will provide you with information about the presence or absence of systemic venous congestion, manifested by hepatomegaly, which may be secondary to right-sided heart failure.

The impulses caused by movement of the heart are common during systole. They are characterized by location, size, and intensity.

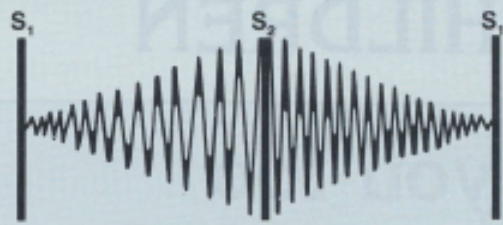
Continued overleaf

Drawing heart sounds and murmurs


Heart sounds and murmurs are commonly represented as a series of vertical lines, each of which represents a component of the complex. Sounds with greater intensity can be illustrated by drawing heavier, taller lines.



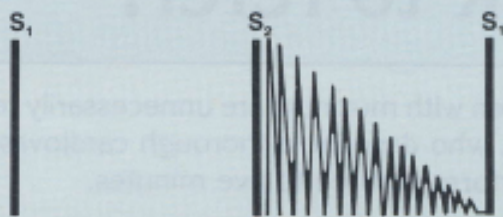
Systolic ejection murmurs



Continuous murmur



Holosystolic murmur



Diastolic murmur

The left ventricular impulse is usually best felt in the fourth and fifth left intercostal spaces, in the midclavicular line, and is usually less than one cm in diameter.

The right ventricular impulse can be palpated in the xiphisternal angle. The right ventricular outflow impulse can be palpated along the left upper sternal border, toward the left shoulder.

This impulse reflects the infundibulum of the right ventricle as well as the main pulmonary artery.

Auscultation

Normal and abnormal sounds

After physical inspection and palpation, you can finally turn to the stethoscope.

Always warm the head of the stethoscope in your hand before placing it on the chest. This small consideration often leads to a much better examination.

Auscultation must be performed the same way everytime so you don't overlook anything.

The routine we use is to listen to the heart rate and rhythm; then, in order, to the first, second, and, if present, the third and fourth heart sounds. Next, we note any extra sounds, especially systolic clicks.

We conclude by listening for murmurs during systole and then during diastole.

First through fourth heart sounds. The first and second heart sounds (S_1 , S_2) are relatively high frequency sounds and are best heard with the diaphragm of the stethoscope. S_3 and S_4 , in contrast, are low-frequency sounds and are best heard with the bell.

Heart sounds should be described by the location on the precordium where they are best heard.

S_1 is usually heard best at the left lower sternal border; S_2 is heard best at the left upper sternal border.

The second heart sound has an aortic and a pulmonary component. The aortic portion (A_2) normally occurs first and the pulmonary component (P_2) second.

The intensity of both components should be evaluated, as well as the amount of splitting during inspiration and expiration. (See "Drawing heart sounds and murmurs".)

The third heart sound, which occurs in early to middle diastole, is caused by rapid filling of the ventricles by blood flowing through the atrioventricular (AV) valves.

The inflow of blood from the atrium into the ventricle causes tensing of the myocardium, papillary muscles, and chordae tendineae and vibrations of the valve leaflets.

S_3 is frequently heard in normal children.

The fourth heart sound occurs late in diastole and is caused by contraction of the atrium, with resultant tensing of the myocardium, papillary muscles, chordae tendineae, and valve leaflets. S_4 is considered a pathologic sound.

To distinguish a widely split S_2 and S_3 , remember that S_3 is better heard at the left lower sternal border, S_2 at the left upper sternal border.

S_2 is better heard with the diaphragm, S_3 with the bell.

Clicks. After critical examination of the heart sounds, listen for additional systolic sounds. Systolic clicks or ejection clicks are often associated with semilunar-valve stenosis (aortic or pulmonary of both).

They occur during early ventricular ejection and therefore are heard during early systole.

Clicks are high-frequency sounds and thus are best heard with the diaphragm. They follow S_1 and should not be confused with splitting of S_2 since S_2 denotes the termination of systole.

Aortic clicks, which are best heard at the apex and left lower sternal border, don't vary from inspiration

to expiration. Pulmonary clicks, in contrast, seem to wax and wane.

Pulmonary clicks are best heard at the left upper sternal border with the diaphragm during expiration.

The sounds become less intense during inspiration.

Murmurs. Murmurs are characterized by intensity, relation to S_1 and S_2 frequency and maximum location and radiation.

Intensity is graded on a scale of one to six. Grade one is barely audible, while grade four is loud and associated with a palpable thrill. Grade six murmurs can be heard even without a stethoscope. Grades 2, 3, and 5 are intermediate grades (Figure 1).

The relation of a murmur to S_1 and S_2 is critical in distinguishing whether it is normal or abnormal (Figure 2a).

Murmurs are generally classified as systolic, diastolic, or continuous. Systolic murmurs occur between S_1 and S_2 ; they may be further differentiated as ejection or holosystolic.

Systolic ejection murmurs have a crescendo-decrescendo shape and begin after S_1 .

Holosystolic (pansystolic) murmurs obliterate S_1 and may go up to S_2 .

Holosystolic murmurs are always pathologic.

However, the majority of systolic murmurs begin after S_1 and end before S_2 ; the normal (functional) murmur is usually of this character.

Diastolic murmurs occur between S_2 and S_1 and are almost always pathologic; they may occur in early, middle, or late diastole.

Continuous murmurs begin in systole after S_1 and continue through S_2 into diastole. They may be normal or pathologic.

Frequency, or pitch, relates to the vibrations per second (Figure 2b).

High-frequency murmurs are generally greater than 100 cycles per second and are heard better with the diaphragm of the stethoscope; low-frequency murmurs are heard better with the bell. Systolic and continuous murmurs are usually of high frequency; diastolic murmurs are generally of low frequency.

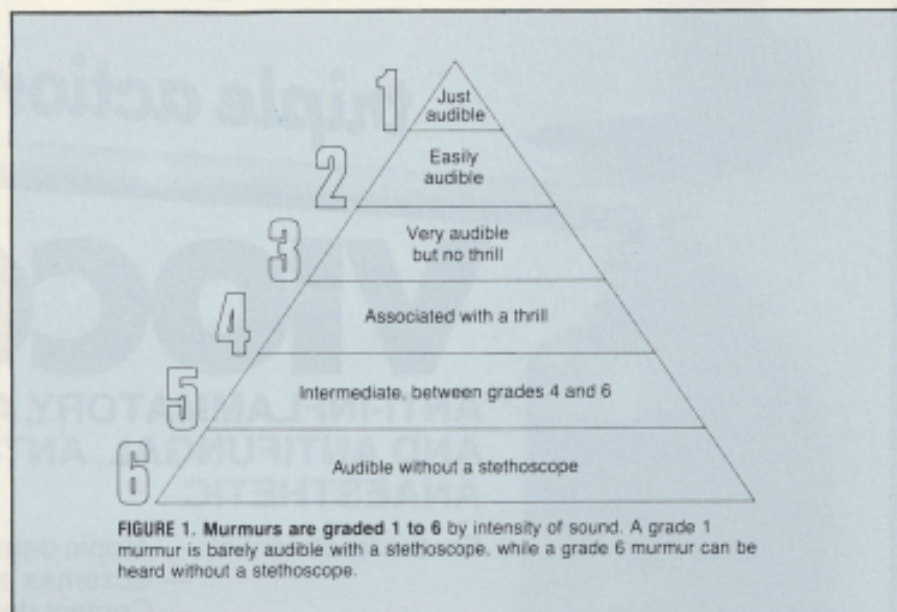


FIGURE 1. Murmurs are graded 1 to 6 by intensity of sound. A grade 1 murmur is barely audible with a stethoscope, while a grade 6 murmur can be heard without a stethoscope.

The fourth characteristic of a murmur is its maximum location on the precordium and the direction in which it radiates.

An early diastolic decrescendo murmur, caused, for example, by pulmonary regurgitation, is heard best at the left upper sternal border with radiation to the left lower sternal border (Figure 2c).

Conditions that affect murmurs

All murmurs may be increased by fever, anxiety, exercise, anemia, and other situations that increase cardiac output. They may also be altered by respiration and changes in position.

Therefore, a normal grade 3 murmur may become grade 4 when a child has a febrile illness. If the same child is examined a week later, when he is afebrile, the murmur may no longer be audible or may be grade 1 or 2 at the loudest. *Don't fall into the trap of making the diagnosis of heart disease in all children with grade 3 murmurs and febrile illness.*

When murmurs are normal

The most frequent normal murmurs heard over the precordium are Still's murmur and pulmonary-flow murmurs. Both occur early in systole and are generally less than grade 3 in intensity.

To determine the cause of the murmur, other components of the

cardiovascular examination are necessary.

Tetralogy of Fallot, for example is diagnosed by the presence of cyanosis and a single second heart sound. Coarctation of the aorta is diagnosed by absence of or decrease in femoral artery pulses.

Atrial septal defect is diagnosed by wide, fixed splitting of S_2

When murmurs are pathologic

Nine defects account for 90 to 95 percent of pathologic murmurs: aortic stenosis, pulmonary stenosis, coarctation of the aorta, atrial septal defect, ventricular septal defect, patent ductus arteriosus, tetralogy of Fallot, mitral insufficiency and aortic insufficiency (Table 1).

The last two are primarily rheumatic heart lesions, while the others are congenital defects.

Figure 3 shows how pathologic murmurs are classified.

Systolic murmurs. Crescendo-decrescendo systolic (ejection) murmurs are heard in cases of aortic stenosis, pulmonary stenosis, coarctation of the aorta, atrial septal defect, and tetralogy of Fallot.

The normal pulmonary-flow murmur and sometimes Still's murmur also are of this type.

By itself, therefore, a crescendo-decrescendo systolic murmur is not diagnostic.

Holosystolic murmurs. Systolic
To page 7

FIGURE 2

Classifying murmurs

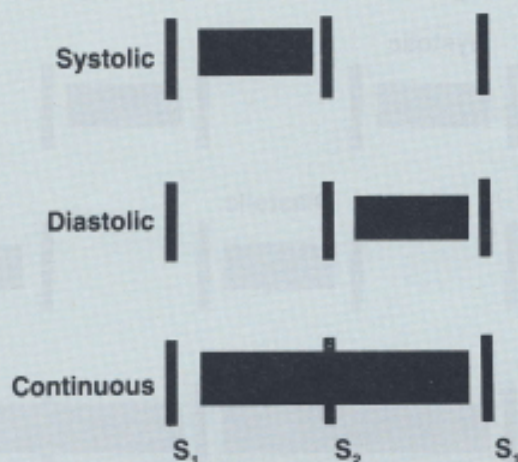


FIGURE 2a. The relationship of a murmur to S₁ and S₂ is critical when determining if it is normal or pathologic.

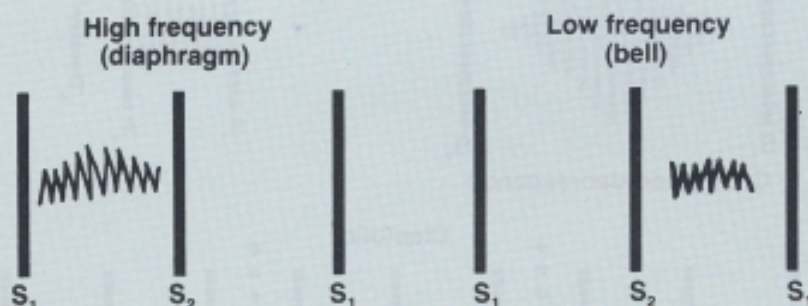


FIGURE 2b. The frequency, or pitch, of a murmur is determined by the number of vibrations per second. High-frequency murmurs (more than 100 vibrations per second) are best heard with the diaphragm of the stethoscope, low-frequency murmurs with the bell.

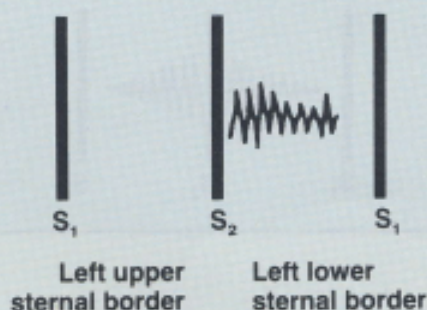


FIGURE 2c. The maximum location on the precordium and the radiation of the murmur can also be used for classification. In this example, an early diastolic decrescendo murmur is best heard at the left upper sternal border and radiates to the left lower sternal border.

From page 5

murmurs that begin with S₁ (obscuring S₁) and continue throughout systole, ending at S₂, are termed holosystolic (pansystolic) murmurs.

Holosystolic murmurs are heard with ventricular septal defect and mitral regurgitation. If S₁ is obscured and S₂ is audible, then the murmur is holosystolic.

If S₁ can be easily heard it is unlikely that the murmur is holosystolic.

Diastolic murmurs. Murmurs may occur in early, middle, or late diastole.

Early diastolic murmurs are caused by aortic- or pulmonary-valve insufficiency. Mid-diastolic murmurs are heard best between the left lower sternal border and the apex.

These murmurs are caused by excess blood flow across an AV valve. This is the time of rapid ventricular filling, when flow across the AV valves is greatest.

Mid-diastolic murmurs may be heard in left-to-right shunt defects (atrial septal defect, ventricular septal defect, or patent ductus arteriosus) because of increased flow across the AV valves.

They may be heard both in cases of mitral insufficiency, because the significant regurgitant flow in systole must come back across the mitral valve in diastole, and in aortic insufficiency (Austin Flint murmur).

Continuous murmurs. The defect that most often leads to a continuous murmur is patent ductus arteriosus.

A ductus murmur differs from a normal cervical venous hum, which is also continuous, in that it doesn't vary with respiration and only rarely does so with changes in position.

The murmur of patent ductus arteriosus is not decreased by jugular compression or by having the child lie down, whereas the cervical hum decreases or disappears with these manoeuvres.

Continued overleaf

Always keep in mind that the diagnosis of heart disease requires a total cardiovascular examination, not just listening to the murmur, and that the examination should follow a strict routine.

A routine will not only keep you from missing something significant, it will make you more efficient. You can often perform a thorough screening examination in three to five minutes.

Making the decision to refer

If you are confident that the murmur is functional, or if the child has a small ventricular defect and is in no distress, it's best not to refer him to a specialist.

Referral for such defects may only result in considerable financial and emotional burden for the family when no treatment is required.

For structural disease, endocarditis prophylaxis is needed. It is also a good idea for children with such murmurs to be re-evaluated at some point before they begin school.

Try to help parents understand what a murmur is — far too few know that most murmurs are not serious.

A case one of us encountered during his cardiac fellowship really illustrates this point.

An 11-year-old girl was brought to the hospital for evaluation. Three years before she had been diagnosed as having a functional murmur.

Since the diagnosis was made, her mother had treated her as a total invalid — carrying her from room to room. Her father had died from a heart attack, and her mother feared the girl was also near death.

Thus, consider all factors, before turning to referral — most of all the possible financial and emotional cost. It's better to prevent unnecessary anxiety than to satisfy your curiosity. □

FIGURE 3

Pathologic murmurs

